


Uro-radiologi

Ultralyd



Arne Hørlyck
Røntgen og Skanning
Aarhus Universitetshospital, Skejby


Oversigt

Normal (UL)-anatomi – teknik

Nyrer

Ureter

Blære




Oversigt

Patologi

Nyrer

Hydronefrose (-ureter)

Blære




Oversigt

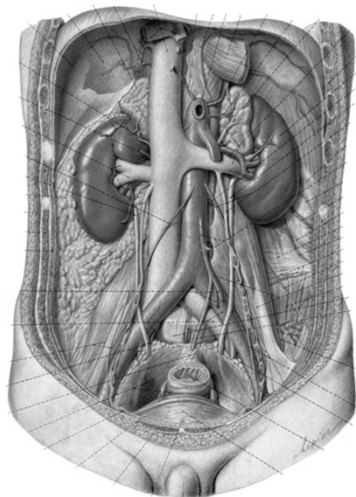
Nyretransplantation

(Prostata)

Scrotum




Anatomi – teknik

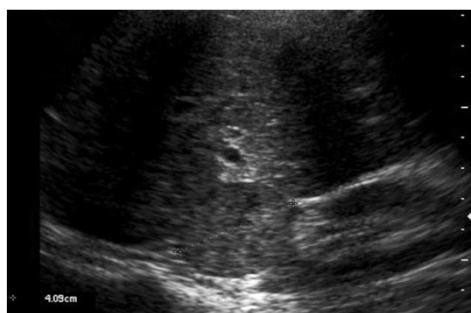


Curved array
 Frekvens?
 Faste?

Fed – mager
 Binyrer


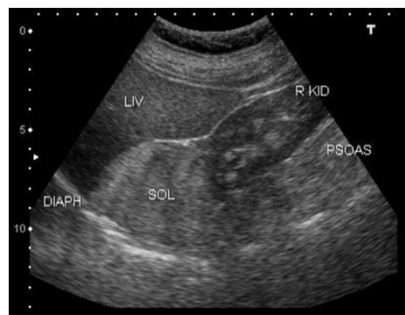


Anatomi – teknik



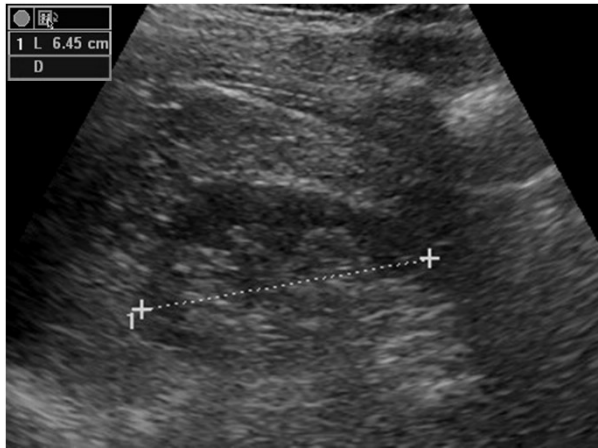
phaeochromocytom

Binyrer
 Tumorer
 Biopsi?



<http://www.ultrasound-images.com/adrenals.htm>

Nyrer – normale




Mål?

længde


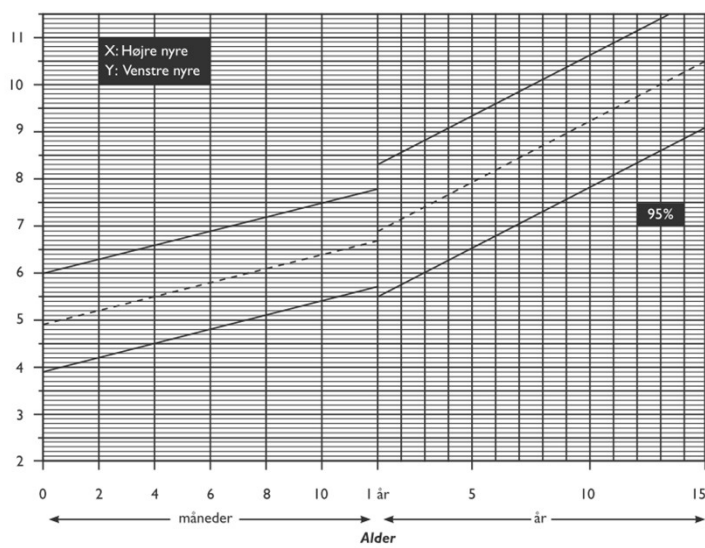
bredde

volumen


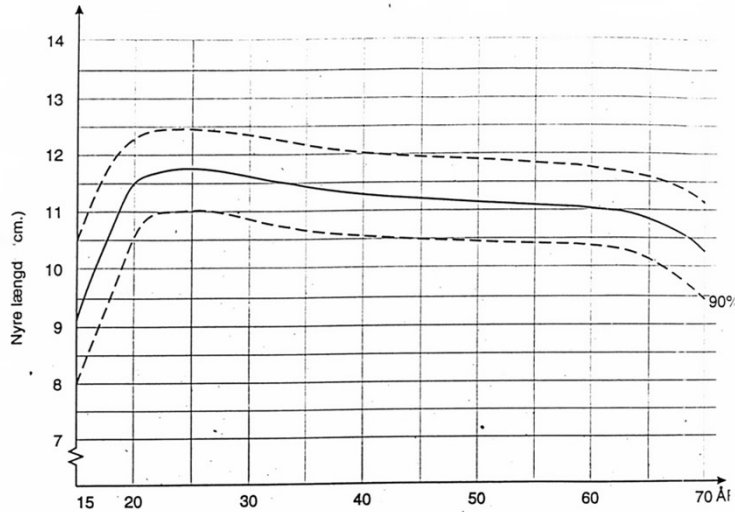
parenchym



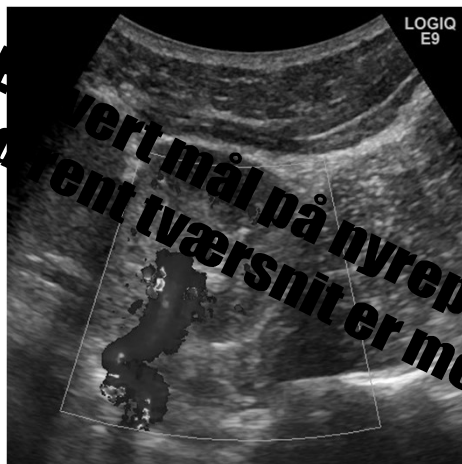Nyrer – normale



Nyrer – normale




Nyrer – normale



Mål?

Nyrepelvis

**Det vertikale mål på nyrepelvis i andet
endeligt tværsnit er meningsløst !!**




Ureter – normal

Mål?

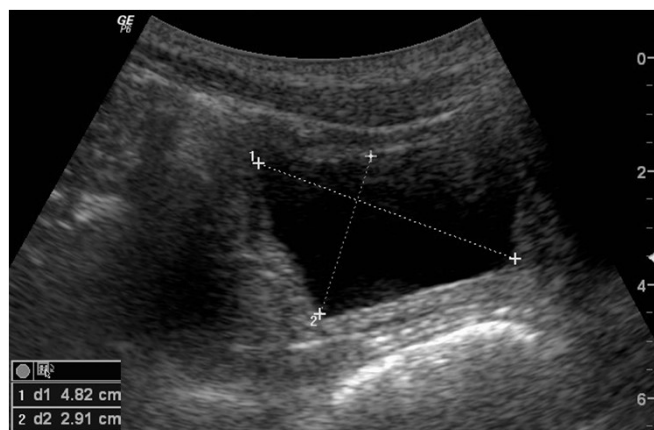
Ikke (altid) synligt

Foran m. psoas


Bag blæren – ostier



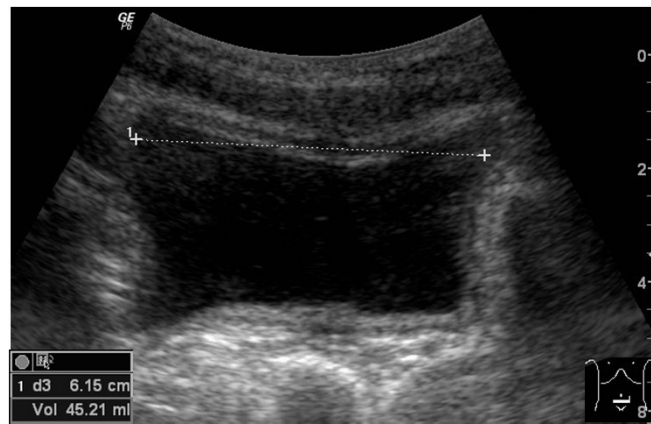
Blære – normal




Sagittalt – mål



Blære – normal




Transverselt – mål



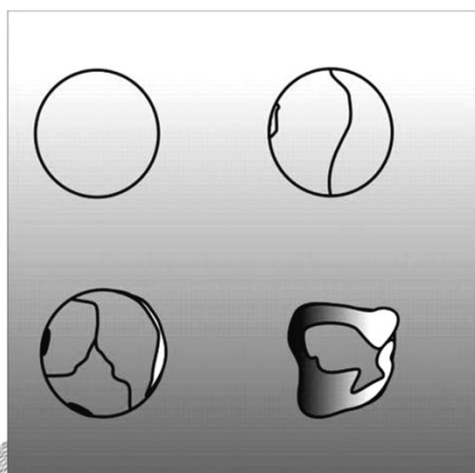
Patologi – nyrer

- Cyster – tumorer
- Medicinske nyresygdomme
- Nyrearteriestenose (RAS)
- Infektioner
- Traume
- Hydronefrose
(Sten)



Cyster – tumorer

Cyster – Bosniak klassifikation



	Ignore	Follow	Excise
Bosniak I, II	→	→	→
Bosniak II F	→	→	→
Bosniak III, IV	→	→	→
Calcification	small smooth, septal milk of calcium	thick nodular	enhancement nodular and wall thickening
Hyperdens	sharp margin < 3 cm not completely intrarenal, homogeneous US: cystic	totally intrarenal, > 3 cm + no enhancing	poorly defined heterogeneous enhancement US: solid
Septations	Thin and smooth	Slightly greater than a hairline	Thick, irregular, nodular enhancement
Enhancement	< 10 HE	10 -15 HE	> 15 HE *
Multiloculated	–	–	All* * unless infection
Nodularity	–	Very small nonenhancing nodules	All others
Wall thickening			All* unless infection

Cyster – tumorer


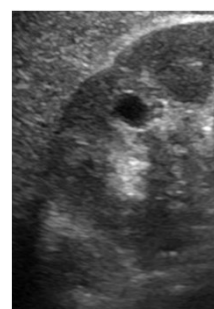
Cyste – ultralyd

tynd væg

ekkotom

for- og bagkantsforstærkning


enhancement



Benigne nyretumorer

Differentialdiagnoser:

- Alle maligne tumorer (RCC)
- Metastase/spredning
- Cyste/cystisk sygdom
- Infektion/inflammation
- Abces
- Hæmatom
- Pseudotumor




Benigne nyretumorer

Angiomyolipom

Ekkorig

Ultralyd ikke sikkert diagnostisk




Benigne nyretumorer

Angiomyolipom

Isolerede angiomyolipomer


Angiomyolipomer associeret med
tuberøs sklerose



Benigne nyretumorer

- Angiomyolipom
- Oncocytom
- Adenom

- Multicystic nephroma
- og andre sjældne



Benigne nyretumorer

Angiomyolipom

Follow-up

< 4 cm

(årlig) kontrol UL (CT)

> 4 cm - symptomer - uafklaret patologi

Nyrebesparende resektion

Cryobehandling


Embolisering

Benigne nyretumorer

Oncocytom

Centralt ar (80%?) – ”spoke wheel sign”

Ultrasound slet ikke diagnostisk



Medicinske nyresygdomme

Klinisk og ultralydmæssigt inhomogen gruppe


Stor – lille – normal

Cortex ekkorig – normal – medulla ekkorig

Cyster – ar

Doppler: Normal – høj perifer modstand (RI)

Systematik findes men ikke specifik (nok)



Medicinske nyresygdomme


Hvorfor ultralyd?

Bestemme nyrestørrelse

Udelukke afløbshindring

Udelukke tumorer og større morfologiske forandringer

Identificere aflejrings sygdomme m.m.



Guide til sikker histologisk nyrebiopsi

Medicinske nyresygdomme

Nyrearteriestenose (RAS)


Central Doppler

høj hastighed (teknisk vanskeligt)

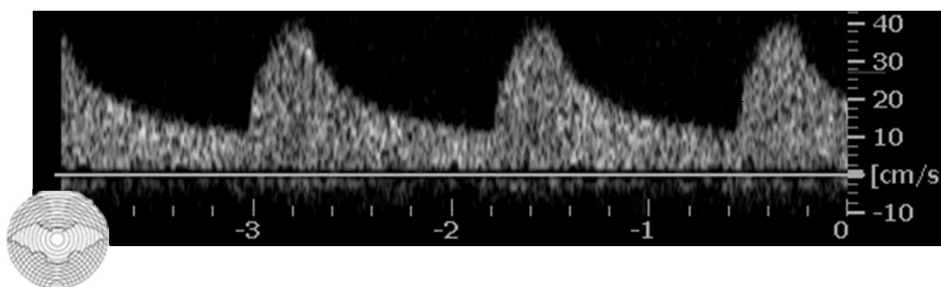
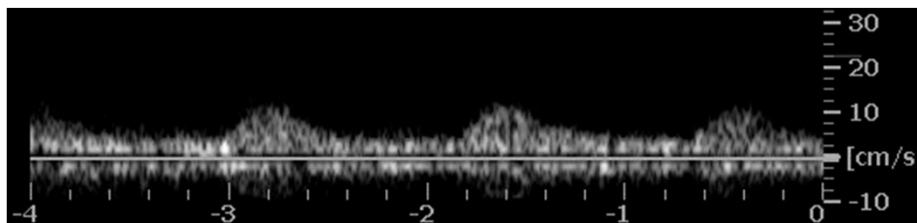
Perifer Doppler

langsom systolisk acceleration

dæmpet kurve (lavt modstandsindex)



Doppler – nyrearteriestenose



Doppler – nyrearteriestenose

Kriterier:

Forskel i nyrelængde $> 1,5$ cm


Forskel i PI $> 0,1$

Medfører

høj sensitivitet ($\approx 100\%$)

moderat specificitet

Sortere før evt. andre metoder



Doppler – nyrearteriestenose

Begrænsninger


ennyret

bilateral stenose

systolisk acceleration

perifer nyresygdom m. PI $> ca. 1,2$

Findes mange andre algoritmer og metoder



Infektioner

Indikation for ultralyd:


Be- eller afkræfte afløbshindring (empyem)

Diagnosticere abscesser

hæmatogen spredning af infektion

infektion i cyste

Ultralydvejledt drænage




Traumer

Få indikationer for ultralyd:

Evt. nogle børn

Evt. nogle kontroller

Evt. ultralydvejledt intervention



Hydronefrose

Ætiologi:

UPS

Sten

Ureterstenose – benign


Ureterstenose – malign

indefra – udefra

Blæretumor

Infravesikal afløbshindring

Find ætiologien!




Hydronefrose

Ingen direkte sammenhæng mellem dilatationsgrad og stenosegrad !

Let stenose i lang tid giver svær dilatation

Svær stenose giver let dilation

Stenose giver tiltagende dilation (en vis tid)



Blære


Tumor

Sten

Koagel

Divertikel

Suprapubisk kateter



Nyretransplantation

Ansamling (beliggenhed/betydning)


Afløbshindring (dilation/ændring)

Venetrombose (sjældent venestenose)

Arteriestenose

Perifer modstand (parenchym-problemer)

Guide til biopsi og graftnefrostomi



Nyretransplantation

(Venetrombose/stenose)


ATIN

Rejektion

akut/kronisk

Intoksikation (cyclosporin m.m.)

Andre generelle medicinske nyresygdomme
(afløbshindring)




Parenchymproblem
Høj perifer modstand

Prostata

Trend:

Urologer (ultralyd – biopsier)


MR (eventuelt incl. biopsi)



Prostata


*Kom til DURS årsmøde
fredag 20. maj 2016*

– Herlev Hospital



Scrotum

Ultrasound er fantastisk !!



Scrotum

Tumor

Epididymitis

Orchitis


Absces

Hydrocele

Spermatocele

Varicocele

(Torsio testis)



Scrotum – tumor


Næsten alle tumorer er maligne

Alle maligne tumorer medfører døden i en ung alder – uden behandling

Næsten alle (> 90%) helbredes

flest og lettest ved tidlig diagnose

Næsten alt udenfor testis er benignt




Scrotum – tumor

Yngre end 50 år: Germinalcellecancer

Ældre den 50 år: Sjældent primær cancer

Lymfom

Metastaser



Scrotum

