13 Patellar and Quadriceps Mechanism

Niels Egund and Leif Ryd

CONTENTS

13.1

Introduction

The extensor mechanism of the knee is composed of the quadriceps muscle group and tendon, the patella, the patellar ligament, the tibial tubercle and the patellar retinaculum. The patellofemoral articulation centralizes the entire mechanism on the anterior surface of the femur, and during knee extension it mediates the forces generated by the largest muscles through the largest lever arms in the body. Minor variations in each component of the extensor mechanism may affect the centralizing function of the patellofemoral joint by altering the patellar tracking in the sulcus of the femur and result in patellofemoral pain and joint degeneration. In spite of extensive experimental and clinical research, the problems of the patellofemoral joint remain a challenge to clinicians, and without a clear understanding of why patellar disorders occur it is not surprising that there is no consensus on how to treat them (Thomee et al. 1999). Neither the widespread use of arthroscopy nor the availability of newer diagnostic imaging techniques such as ultrasound, computed tomography (CT) and magnetic resonance (MR) imaging has so far contributed significantly to the understanding of disorders related to dysfunction of the extensor mechanism or to the traditional treatment of patellofemoral disorders (Insall 1995).

Clinical assessment and imaging of the normal and injured patellofemoral joint require knowledge not only about the anatomy and biomechanics of the knee and the extensor mechanism, but also about the site and pathoanatomical characteristics of the different disorders in question. In each clinical situation, the (Merchant 1988) classification system of patellofemoral disorders (Table 13.1) may be useful in identifying the different abnormalities. The system defines the etiology and pathomechanics of patellofemoral disorders and categorizes the diagnoses such that relevant examination plans can be initiated and treatment suggested. However, in the absence of evolution in the classification, examination, and treatment of patellofemoral disorders, it is felt by the authors of the present chapter that some fundamentals of biomechanics of the knee have been ignored for many years and that the relation between some scientific observations and commonly observed pathoanatomical and surgical findings has been overlooked (Fulkerson 1997; Scuderi 1995).

N. Egund, MD
Professor, Department of Radiology, Aarhus University Hospital, Noerrebrogade 44, 8000 Aarhus C, Denmark
L. Ryd, MD
Associate Professor, Department of Orthopedics, University Hospital of Lund, 22185 Lund, Sweden

Table 13.1. The Merchant classification system of patellofemoral disorders

- *I. Trauma (conditions caused by trauma in the otherwise normal knee)*
  - A. Acute trauma
    - 1. Contusion
    - 2. Fracture
      - a) Patella
      - b) Femoral trochlea
      - c) Proximal tibial epiphysis (tubercle)
    - 3. Dislocation (rare in the normal knee)
    - 4. Rupture
      - a) Quadriceps tendon
      - b) Patellar tendon
  - B. Repetitive trauma (overuse syndromes)
    - 1. Patellar tendinitis ("jumper's knee")
    - 2. Quadriceps tendinitis
    - 3. Peripatellar tendinitis (e.g., anterior knee pain in the adolescent caused by hamstring contracture)
    - 4. Prepatellar bursitis ("housemaid's knee")
    - 5. Apophysitis
      - a) Osgood-Schlatter disease
      - b) Sinding-Larsen-Johansson disease
  - C. Late effects of trauma
    - 1. Post-traumatic chrondromalacia patellae
    - 2. Post-traumatic patellofemoral arthritis
    - 3. Anterior fat pad syndrome (post-traumatic fibrosis)
    - 4. Reflex sympathetic dystrophy of the patella
    - 5. Patellar osseous dystrophy
    - 6. Acquired patella infera
    - 7. Acquired quadriceps fibrosis
- *II. Patellofemoral dysplasia*
  - A. Lateral patellar compression syndrome
    - 1. Secondary chondromalacia patellae
    - 2. Secondary patellofemoral arthritis
  - B. Chronic subluxation of the patella
    - 1. Secondary chondromalacia patellae
    - 2. Secondary patellofemoral arthritis
  - C. Recurrent dislocation of the patella
    - 1. Associated fractures
      - a) Osteochrondral (intra-articular)
      - b) Avulsion (extra-articular)
  - D. Chronic dislocation of the patella
    - 1. Developmental
    - 2. Acquired
- *III. Idiopathic chondromalacia patellae*
- *IV. Osteochondritis dissecans*
  - A. Patella
  - B. Femoral trochlea
- *V. Synovial plicae (anatomic variants made symptomatic by acute or repetitive trauma)*
  - A. Pathologic medial patellar plica ("shelf")
  - B. Pathologic suprapatellar plica
  - C. Pathologic lateral patellar plica
- *VI. Iatrogenic disorders*
  - A. Iatrogenic medical patellar compression syndrome
  - B. Iatrogenic chronic medial subluxation of the patella
  - C. Iatrogenic patella infera

It has generally been accepted that radiographic assessment of the femorotibial joint spaces should be performed in the standing, weight-bearing position with the knee in semiflexion. With the patient standing on one leg, this AP or PA radiographic view also allows assessment of varus or valgus angulations and subluxation. Clinical examinations and tests as well as imaging of the patellofemoral joint are in general performed in the non-weight-bearing supine position; however, it is uncertain and unexplored how valid these measurements are for performance in the standing position, in which disorders develop and may give rise to pain. Following the monograph of (AHLBACK 1968), the authors of the present chapter were brought up with weight-bearing radiographic views of the knee including the patellofemoral joint, clinically as well as in research. Recently, during ongoing research, we became aware of some major differences between weight-bearing and non-weight-bearing imaging, which at present may be considered controversial but will contribute to changes in the understanding and treatment of patellofemoral disorders.

13.2
Anatomy

The patellofemoral joint consists of the trochlea (patellar groove, femoral sulcus) of the femur and the patellar articular surfaces (Fig. 13.1). The embryology of the patella and the femoral trochlea is fascinating (LANGER 1929), with early essential characteristics of the adult. Initially, the medial and lateral facets are equal in size, but after 23 weeks' gestation the lateral facet tends to predominate. Before this time the lateral facet of the trochlea has a greater transverse width and is anteriorly more prominent, although the patella is positioned distal to and without contact to the trochlea. During growth and following function, the shape of the patella may be modified. WIBERG (1941) described three configurations of the patellar joint (Fig. 13.2). Wiberg type II (Fig. 13.1) has a smaller medial facet and represents the most common patellar anatomy. WIBERG suggested that type III may be correlated to chondromalacia, but this has not been confirmed. A number of different anatomical variations and ossification variants may be observed (KEATS 1996).

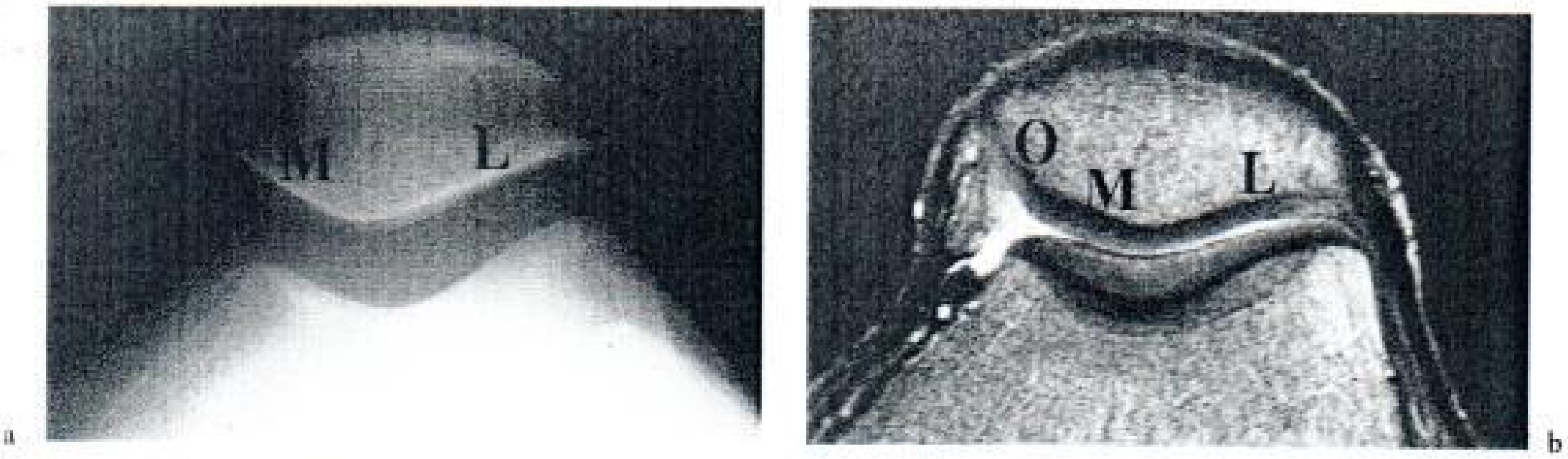

Fig. 13.1a, b. Normal patellofemoral joint in a 24-year-old male. a Axial radiographic view and b transaxial MR sectioning through the middle of the patella obtained by a proton fat-saturated sequence with the knee in 20° of flexion. The lateral (*L*) facets of the patella and the femoral condyle are larger than the medial facets (*M*), and the depth of the osseous condylar groove is greater than the cartilaginous. The medial patellar cartilaginous facet is separated from the odd facet (*O*) by a ridge



Fig. 13.2a, b. Axial radiographic views of two patellofemoral joints. Wiberg type I (a) is rare and the medial (*M*) and lateral (*L*) facets are almost equal in size. Wiberg type III (b) has a large lateral (*L*) and a small medial (*M*) facet and is commonly associated with a large sulcus angle. Type II, the most common type, is shown in Fig. 13.1

13.2.1
Soft Tissue Stabilizers

The patella is the turning point of the converting retinacular structures, which consist of ligaments, muscles and joint capsule (Fig. 13.3). With the large range of motion within the patellofemoral joint, the joint capsule, with an extensive synovial expansion, is poorly defined and does not contribute to patellar stabilization.

13.2.1.1
Active Stabilizers of the Patellofemoral Joint

The active stabilizers of the patellofemoral joint consist of the four main muscles of the quadriceps, which fuse distally into the quadriceps tendon. At the insertion into the patella, three separate layers of the quadriceps tendon can be identified (Fig. 13.4). The rectus femoris originates from two attachments on the ileum and inserts into the anterior top and the

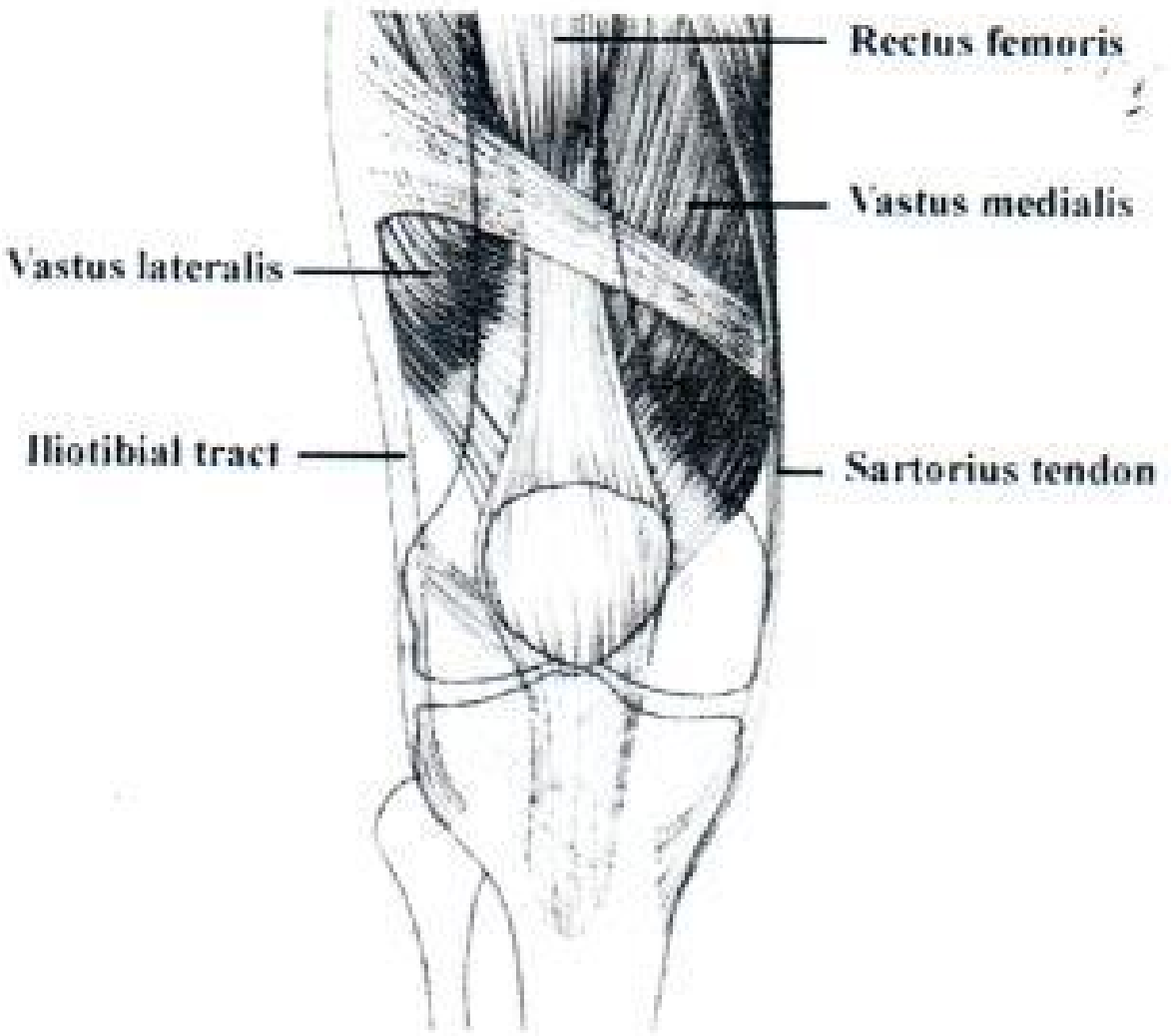

Fig. 13.3. The superficial portion of the extensor apparatus. Medially there is a fibrous attachment between the patella and the iliotibial tract, and laterally an attachment to the sartorius tendon

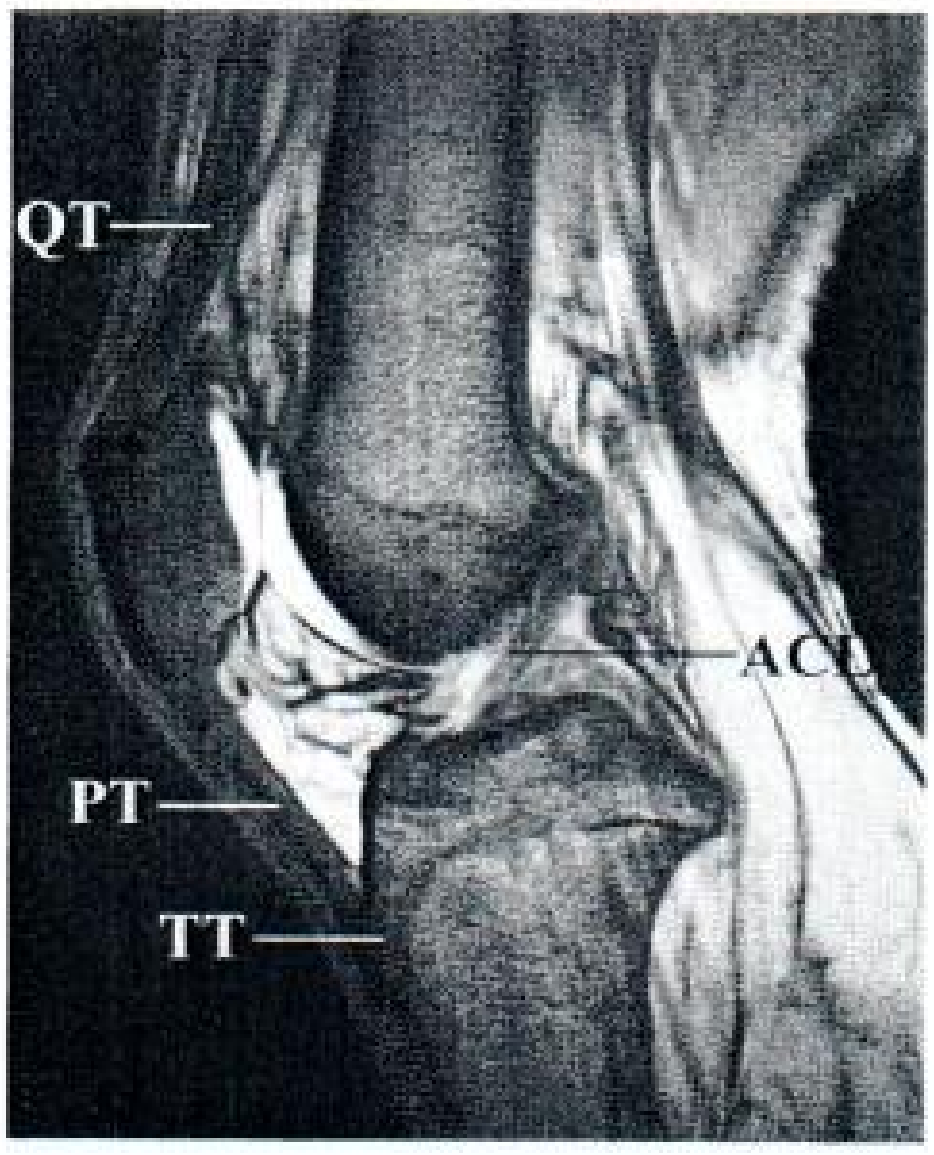

Fig. 13.4. Normal MR anatomy in the sagittal plane of the extensor apparatus, showing the separate layers of the quadriceps tendon (*QT*). The patella is attached to the tibial tuberosity (*TT*) by the patellar tendon (*PT*). *ACL*, Anterior cruciate ligament. There is a bright signal from the patellar and femoral cartilage on this T1-weighted Flash 2D sequence

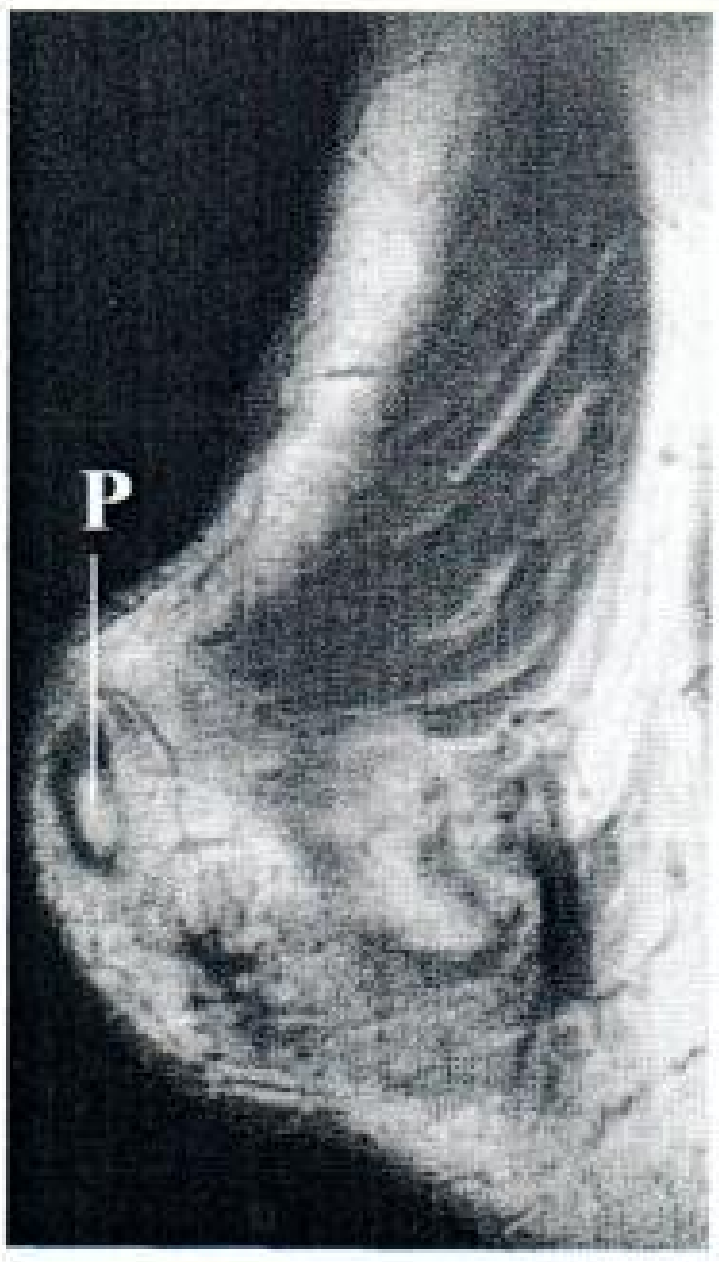

Fig. 13.5. The normal MR anatomy of the vastus medialis and its attachment to the medial portion of the patella (*P*). The course of the distal fibers of the muscle and its tendon is almost horizontal. T1-weighted sequence

superior third of the anterior surface of the patella, with some fibers continuing into the patellar tendon. The vasti medialis and lateralis originate from the superomedial and lateral aspect of the femur, respectively, and unite in the midline in a solid aponeurosis that inserts into the base and medial and lateral aspect of the patella. In the most distal portion of both the vastus medialis and the vastus lateralis there are separate small muscle groups with an oblique orientation of their muscle fibers, termed the vastus medialis obliquus (Fig. 13.5) and vastus lateralis obliquus, respectively. These provide a direct medial and lateral pull on the extensor mechanism and are important for patellar balance in the femoral trochlea. The vastus intermedius inserts with a thin but broad tendon into the base of the patella posterior to the other tendons.

13.2.1.2
Passive Stabilizers

The patellar tendon, the central portion of the quadriceps tendon, and the medial and lateral retinacula are the passive elements of soft tissue stabilization. The patellar ligament connects the patella with the tibial tuberosity and has a length of 4–6 cm, a width of 25–40 mm, and a thickness of 6–8 mm (Fig. 13.4). The orientation of the patellar tendon is parallel to the long axis of the lower extremity. The retinacula are composed of superficial and deep layers (Figs. 13.6, 13.7). The thin oblique superficial retinacula link the patella and patellar ligament

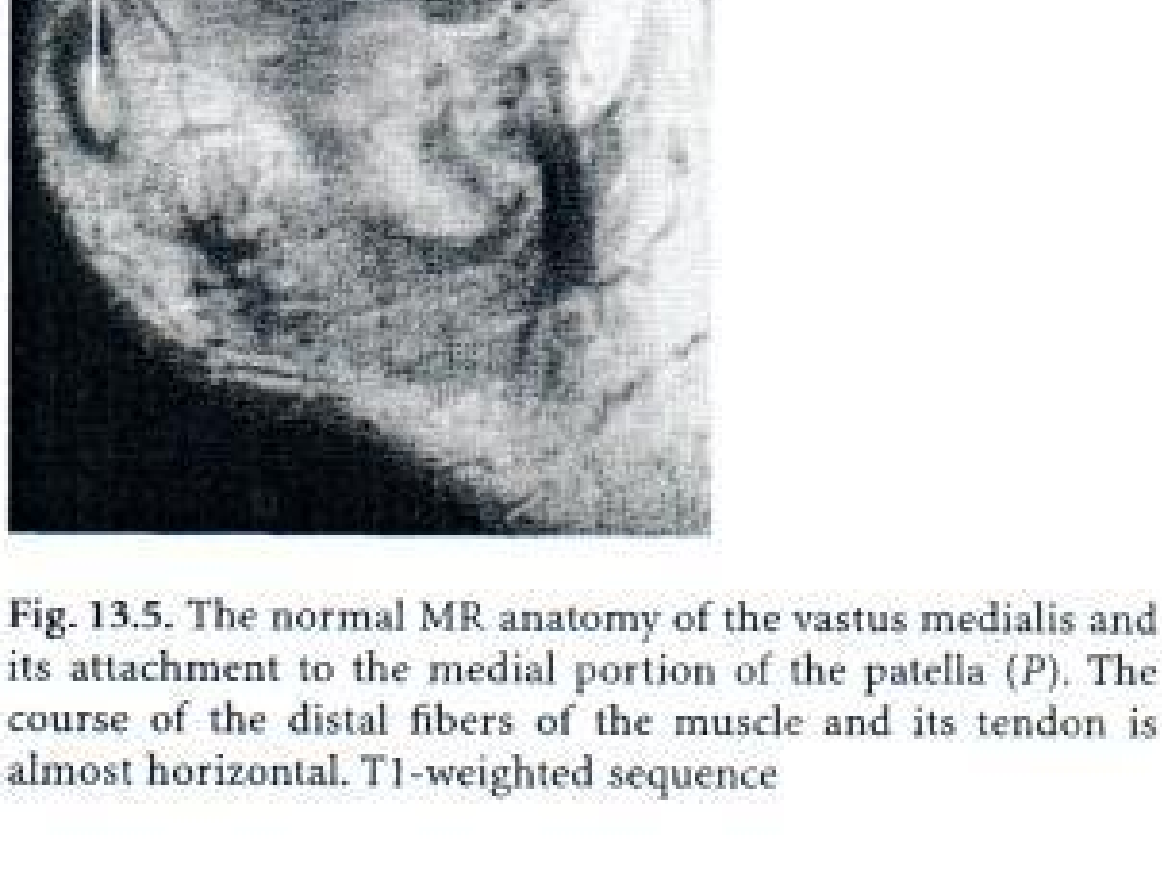

Fig. 13.6. Normal MR anatomy of the patellar retinaculum on a T1-weighted Flash 2D sequence. The superior portion of the medial patellofemoral ligament (*MPFL*) has a broad fibrocartilaginous attachment to the odd facet (*O*) of the patella and is dorsally attached to the femoral condyle and medial collateral ligament (*MCL*) with extension to the fascia of the dorsal muscles. *LPFL*, Lateral patellofemoral ligament

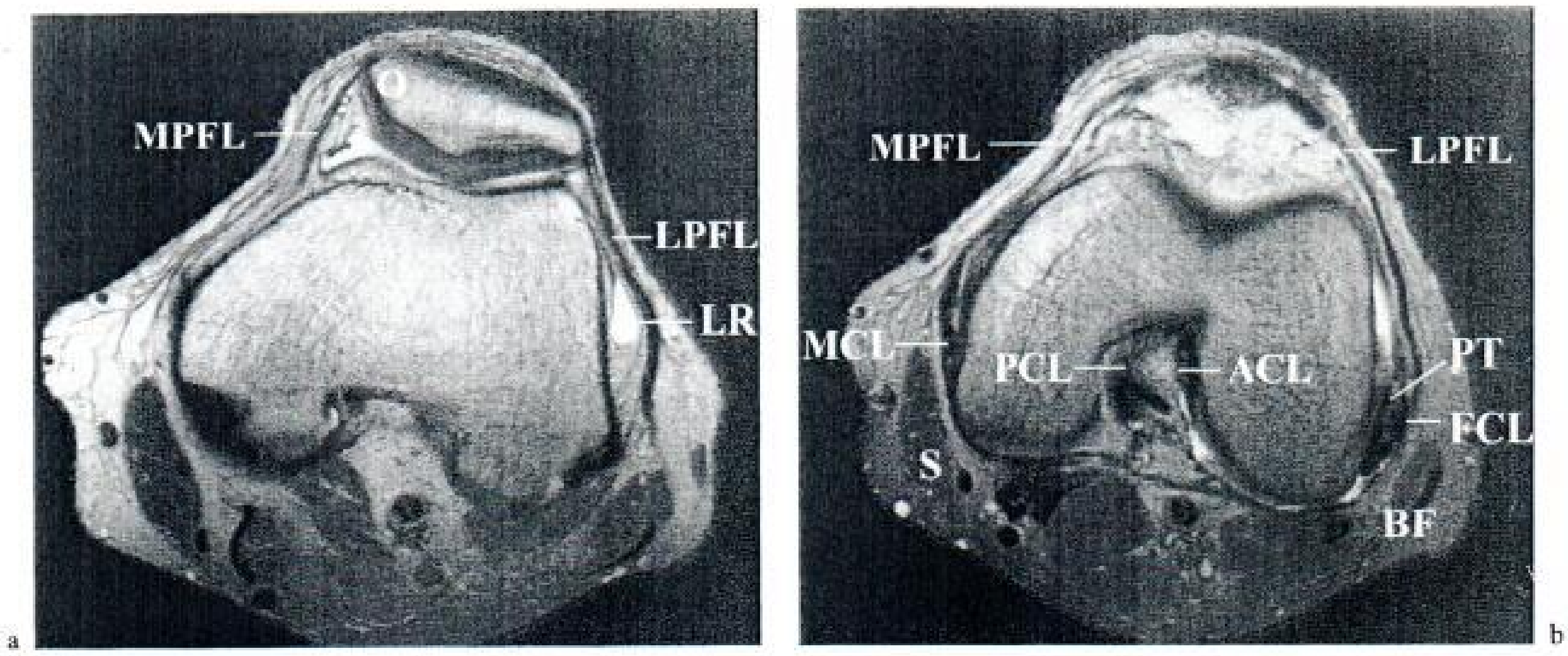

Fig. 13.7. Normal MR anatomy of the patellar (a) and infrapatellar (b) portions of the medial and lateral retinacula on a proton fat-saturated sequence. *PCL*, Posterior cruciate ligament; *ACL*, anterior cruciate ligament; *LR*, lateral synovial recess; *PT*, popliteal tendon; *BF*, biceps muscle and tendon; *FCL*, lateral collateral ligament; *S*, sartorius muscle. Other abbreviations are as in Fig. 13.6

medially to the tendon of the sartorius and the deep fascia of the leg and laterally to the fascia lata. In the deeper layers, capsular condensations form fibrous layers that link the patella to the medial and lateral femoral epicondyles and the anterior aspect of the menisci (Fig. 13.49). They include the medial and lateral patellofemoral ligaments and, below, the medial and lateral meniscotibial patellar ligaments. In between the medial patellofemoral and the meniscopatellar ligament, the deep transverse retinaculum courses directly from the iliotibial tract to the patella. It is supposed that the soft tissue stabilizers are strongest on the lateral side. The normal MR and sonographic appearances of the patellar retinaculum were described in detail by Starok et al. (1997).

13.3 Biomechanical Considerations

The main biomechanical function of the patella is to improve the efficiency of the quadriceps by increasing the lever arm of the extensor mechanism. Throughout the range of motion, the patella displaces the quadriceps tendon and the patellar tendon away from the femorotibial contact point and increases the force of extension by as much as 50% (Fig. 13.8). The degree of tension of the extensor mechanism and the resultant force, the patellofemoral joint reaction force, acting perpendicular to the articular surfaces, has been measured and calculated by numerous authors, with considerable divergence of quantitative values. These values depend on various factors, including body weight, quadriceps force, angle of flexion, and individual anatomic factors. It is beyond the scope of this textbook to go into detail on these considerations, an overview of which can be obtained from orthopedic textbooks (Fulkerson 1997; Scuderi 1995). However, the patellofemoral joint reaction force may vary

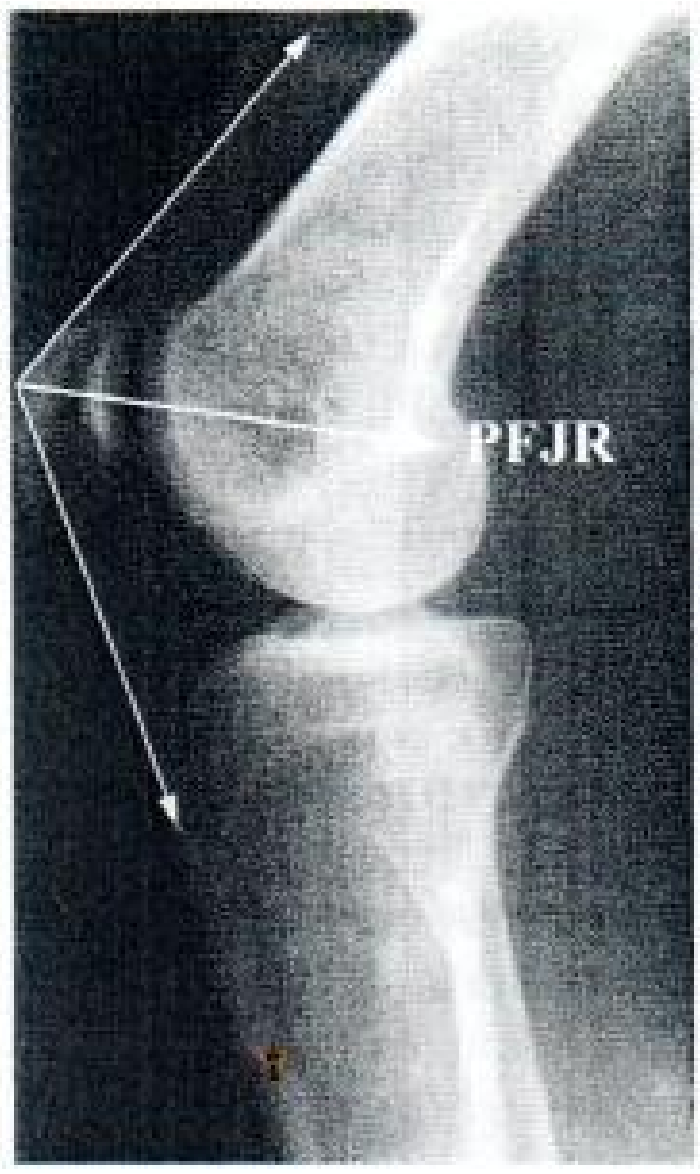

Fig. 13.8. The patellofemoral joint reaction force (*PFJR*) is the resultant vector of the quadriceps and patellar tendon force

between 0.5 times the body weight at walking and 25 times the body weight at weight lifting and at 90° of flexion of the knee. Thus in the assessment of patellofemoral disorders, occupational and sports activities are one of the cornerstones of patient history, especially when dealing with overuse syndromes and late effects of these.

The second, and from an imaging point of view most essential, part of the biomechanics of the extensor mechanism is the behavior of patellar tracking. Clinical as well as radiological assessment of the patellofemoral joint requires an understanding of those normal and abnormal factors which influence the patella in its ride through the femoral trochlea during flexion and extension of the knee.

13.3.1
Patellar Tracking and the Q Angle

The Q angle is the angle formed by a line drawn from the anterior superior iliac spine of the pelvis through the center of the patella and a line drawn from the patella to the center of the tibial tuberosity (Fig. 13.9). The Q angle is a common clinical measure and is frequently discussed as a reflection of the valgus angle of the extensor mechanism, with the underlying assumption that the larger the Q angle is, the larger the lateral moment on the patella. The clinical measurement of the Q angle is most commonly performed with the patient in the supine position with the knee in extension, although standing measurement would reflect weight-bearing function more accurately (Post 1997). Different publications cite different values for the normal Q angle, from 11° to 20°, and it is slightly greater in standing subjects (Woodland and Francis 1992). Although measurements of the Q angle are extensively used by orthopedic surgeons clinically as well as in the planning of surgical procedures, it has been claimed (Post 1997) that no direct correlation with the incidence of patellofemoral disorders has been established by scientific criteria.

The Q angle is helpful in understanding the function of the extensor mechanism and patellar tracking. In the literature it has generally been agreed that, in the terminal 30° from flexion to extension, the "screw home" mechanism rotates the tibia outward relative to the femur, displacing the tibial tuberosity laterally and increasing the Q angle (Fig. 13.9). With a lateral position of the tibial tuberosity (large Q angle), tension on the quadriceps will tend to produce a lateral displacement vector of the patella, a decrease in the Q angle, esisted by the vastus medialis obliquus, the medial retinaculum and the lateral facet of the trochlea. With the knee in full extension and the quadriceps contracted, the patella lies proximal to the trochlea. During the first 30° of flexion, the tibia rotates inward, decreasing the Q angle and also the lateral vector, and the patella is drawn into the trochlea from the lateral side (Hungerford and Barry 1979). These considerations are in accordance with and to a great extent based upon classical interpretations of the axial radiographic view of the patellofemoral joint (Laurin et al. 1978; Merchant et al. 1974) and transaxial static and kinematic imaging with CT (Delgado-Martins 1979; Dupuy et al. 1997; Martinez et al. 1983a,b) and MR imaging (Brossmann et al. 1993, 1994; Shellock et al. 1989). All of these investigations were performed in the supine position and so far, their performance for the biomechanics and patellar tracking in the standing weight-bearing position has not been established using scientific criteria.

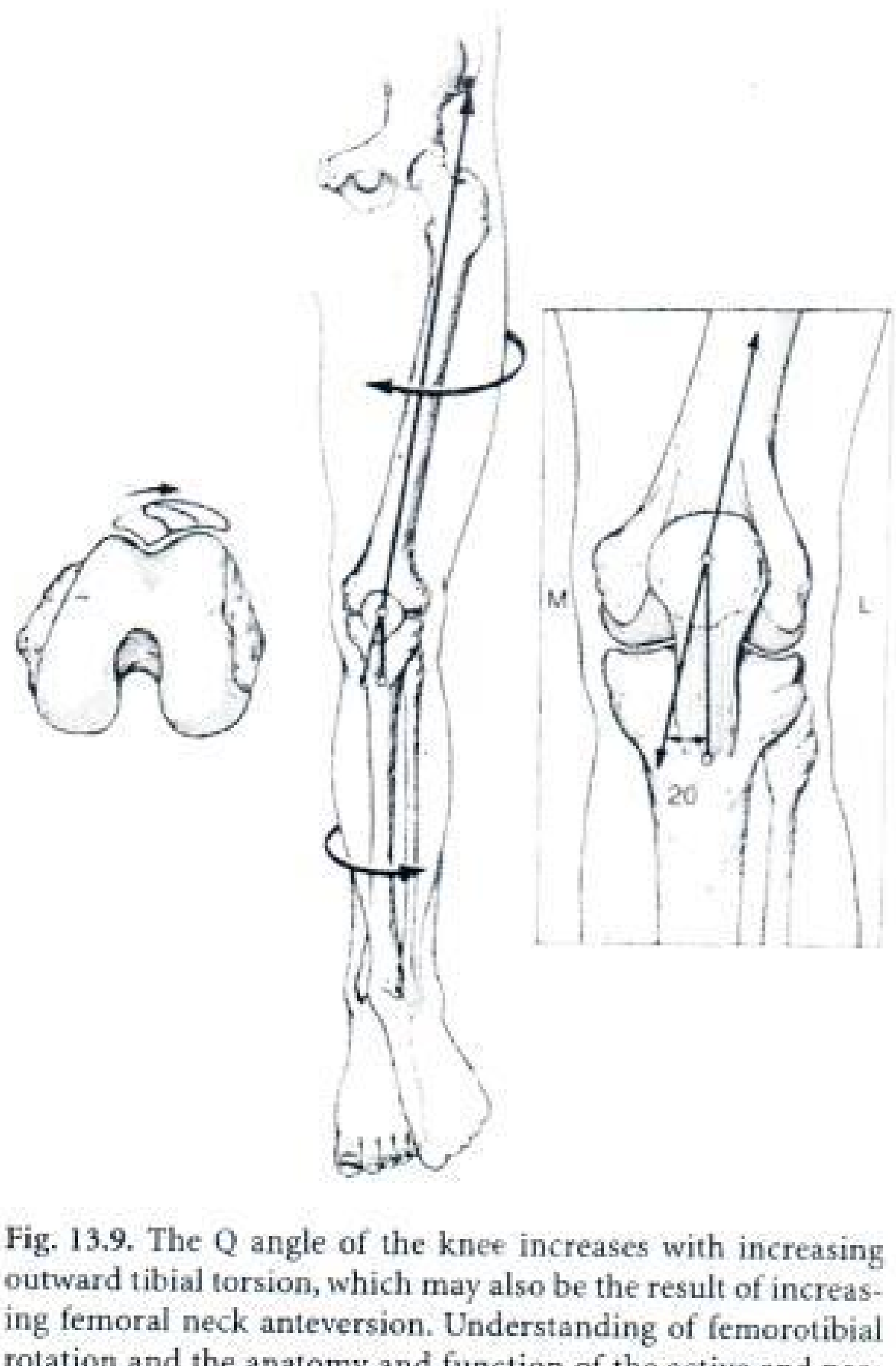

Fig. 13.9. The Q angle of the knee increases with increasing outward tibial torsion, which may also be the result of increasing femoral neck anteversion. Understanding of femorotibial rotation and the anatomy and function of the active and passive stabilizers of the patellofemoral joint (Fig. 13.3) is a perquisite for understanding of abnormalities of the extensor mechanism. (Scuderi 1995)

Roentgen stereophotogrammetric analysis, described below, allows very accurate measurements of motion between rigid bodies in all three planes, including rotation (Selvik 1974), and has been extensively used in orthopedic and biomechanical research. Using this technique, Blankevoort et al. (1988) demonstrated that motion patterns of the knee are highly susceptible to small changes in the external load configuration and specifically that the "screw home" mechanism is not an obligatory effect of the passive joint characteristics, but a direct result of the external loads. This supports the observations reported by Stein et al. (1993), who imaged fluoroscopically the patellofemoral joint of healthy volunteers in the anteroposterior plane during walking. They recorded a uniform pattern of medial excursion of the patella relative to the femur, with a sudden shift from lateral to medial, and concluded that contrary to conventional understanding, the patella deviates medially rather than laterally during walking.

13.4
Clinical and Pathologic Considerations

The multifactorial etiologies of anterior knee pain can be related to variants of the anatomy of the patella and alterations in the tensile forces of the extensor mechanism applied to the joint surfaces of the patellofemoral joint, generated during the complex movement of the joint. These alterations may be caused by overuse, disuse, and injuries to bone, cartilage and supporting soft tissue structures. Although the classification of patellofemoral disorders (Table 13.1) devised by Merchant (1988) provides a useful framework for the clinical and imaging approach to diagnosis and treatment, it is felt that it fails to recognize and interpret the pathogenesis of the most common disorders of the patellofemoral joint.

Patellar articular cartilage presents different modes of degeneration. *Chondrosis* signifies a disorder affecting only the articular cartilage and *arthrosis*, a disorder affecting all three components of the joint: cartilage, subchondral bone, and synovial membrane. *Chondromalacia patellae* is a term applied to a syndrome of anterior knee pain in adolescents and young adults (Aleman 1928; Wiberg 1941) and the pathoanatomical appearances are described as softening (malacia), edema, and swelling of the cartilage. A proposed classification of the surgical and arthroscopic severity of chondromalacia (Fulkerson and Shea 1990) is almost identical to that of arthrosis: grade 1 represents softening and swelling of the cartilage; grade 2 is cartilage breakdown (fibrillation) of one half inch or less; grade 3 is cartilage breakdown of greater than one half inch; and grade 4 is erosion of cartilage down to bone (Outerbridge 1961). This classification is also useful in the grading of joint degeneration at MR imaging (Chap. 3). The term "chondromalacia patellae," however, has become controversial since it may cover a large number of disorders leading to patellofemoral pain (Radin 1979) in which loss of patellar cartilage is not documented, is not present, or occurs in combination with other abnormalities such as bursitis (pre- and infrapatellar, pes anserinus), the plica syndrome, the fat pad syndrome, arthrosis, synovitis, and meniscal tears.

The terms "*patellar tilt-compression*" and "*excessive lateral pressure syndrome*" (ELPS) were introduced by Ficat and Hungerford (1977). These conditions are characterized clinically by pain and radiologically by lateral patellar tilt as evidenced on axial patellofemoral radiography, CT, and MR imaging (Fulkerson 1997). They are commonly associated with chondromalacia patellae and, when articular manifestations occur, the site of cartilage lesions are the same. Classically, it is stated that the medial facet of the patella is the typical and primary site of cartilage lesions in chondromalacia, particularly about the ridge that separates the medial and odd facets (Wiberg 1941; Insall et al. 1976). The cartilage changes on the medial patellar facet with a supposed deficient contact to the femoral trochlea (Henche et al. 1981) have been attributed to various etiologic factors. Several authors have pointed out the tendency for cartilage that is out of contact with other cartilage to undergo surface fibrillation (Goodfellow et al. 1976) and lose an appropriate mechanism of synovial fluid nutrition (Fulkerson 1983; Laurin et al. 1978).

13.4.1
The Request for Imaging – History and Physical Examination

Accurate, concise clinical evaluation of the patient with a suspected knee disorders is almost invariably suggestive of a working diagnosis. Together with the clinical information, this working diagnosis forms the cornerstone for tailoring the radiological examination and, indeed, for the interpretation of images. Therefore it is essential that the request for imaging is seen by an experienced radiologist and that the radiographer is provided with a precise written instruction explaining the examination protocol to be followed. The clinical information should include previous relevant imaging findings, trauma, and treatment, and should encompass the spine, hips, and ankle. Any history or signs of arthritis, and especially seronegative arthritis or spondylarthropathy, may be decisive for selection of the type of examination and for differential diagnosis (enthesopathies are commonly misinterpreted). In Scandinavia many departments of radiology routinely report the examination findings before the patient leaves the department, which provides an opportunity for patient contact and for supplementary radiographic views or immediate ultrasound when relevant. As a result, many adults and elderly patients admitted for knee complaints leave our departments with a diagnosis of hip joint synovitis and/or arthrosis.

13.5
Routine Radiography

Our standard radiographic examination is sufficient for the evaluation of most middle-aged and elderly patients with nontraumatic knee complaints. The examination comprises the three standard radiographic views – lateral and posteroanterior views of the knee and transaxial view of the patellofemoral joint – all obtained in the standing, weight-bearing position. For examination in all three views, the knee is supported by a device (Figs. 13.10, 13.11, 13.16) which represents a simple composition of two separate devices (Egund 1986; Egund and Friden 1988) and has been adapted by several departments of radiology in Denmark. The background for the construction of the device is the normal tibial plateau angle (Figs. 13.12, 13.14) relative to the tibial crest of 14° (±3.6°, range 7°–22°) (Moore and Harvey 1974) and the normal alignment in relation to the vertical plane of the posterior articular surface of the patella in 15° of inclination of the lower leg, when in the standing, weight-bearing position (Egund 1986).

13.5.1
Lateral View

Positioning of the patient with close contact between the entire anterior surface of the lower leg and the plate of the device (Figs. 13.10, 13.12) is a prerequisite for optimizing the posteroanterior and axial views. The rotational position of the foot should be the same as observed at gait, which ensures an almost true lateral view of the femoral condyles. We use a knee flexion of between 25° and 35°. The rotational femorotibial laxity in the weight-bearing position is ±12°, and therefore the patients are asked to look straight forward. Shortly before exposure, the patient is asked to place his or her weight on the leg being examined, simulating a runner's position of the knee before extension. The lateral radiographic view in

Fig. 13.10. Device for lower leg support and patient position for the lateral radiographic view of the knee

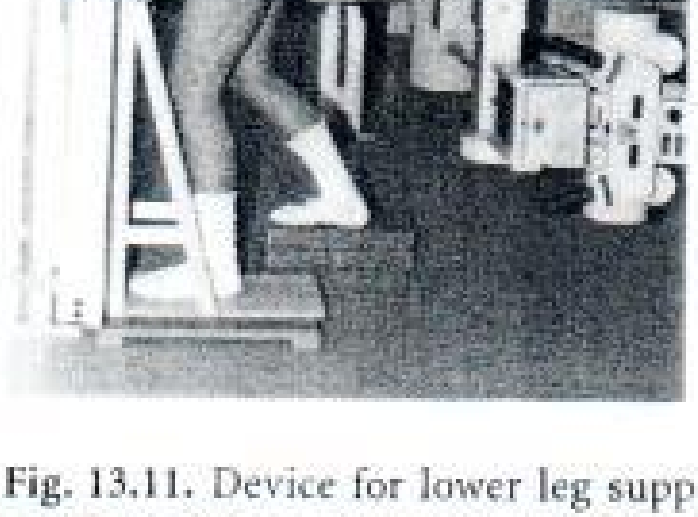

Fig. 13.11. Device for lower leg support and patient position with 30° of knee flexion for the anteroposterior radiographic view. The "one-leg stand" is confirmed by the active lateral quadriceps muscle

this position also allows assessment of sagittal laxity (Fig. 13.13) (Egund and Friden 1988; Egund et al. 1993; Friden et al. 1992, 1993). The slopes of the tibial plateau and the articular surface of the patella are estimated on the preview screen or developed film (Figs. 13.12, 13.32), as well as the position of the central beam.

Fig. 13.12. Normal true lateral radiographic view of the knee obtained in the standing position using the described device (metal screws are visible). The tibial plateau is horizontal and the position is adequate for the anteroposterior projection of the femorotibial joint space. There is a dorsal slope of the articular surface of the patella, the position being less optimal for the axial radiographic view with a vertical beam direction

13.5.2
Posteroanterior View

The slope of the tibial plateau is adjusted to horizontal either by placing a wedge-shaped cushion between the plate of the device and the knee (inclination of the lower leg is decreased) at anterior slope on the lateral view or by placing the foot more posteriorly (inclination of the lower leg is increased) at dorsal slope. The rotational position of the foot and knee flexion (25°–35°) should be as for the lateral view. The weight-bearing, one leg standing position (Fig. 13.11) is strenuous, and a fast exposure is required to avoid knee extension, upon which joint space narrowing may be lost. The use of the device allows serial exposures in different degrees of flexion. It must be mentioned that when assessing the femorotibial joint spaces the slope of the medial and lateral tibial articular surfaces in the sagittal plane is rarely the same (Figs. 13.14, 13.15): the mean difference is 3° (range 0° – 5°), and in abnormal conditions it may reach 9° (Egund et al. 2000). Therefore it is not possible to accurately measure both medial and lateral femorotibial minimal joint spaces (Boegard et al. 1998b; Buckland-Wright 1994) on single AP or PA radiographs.

13.5.3
The Standing Axial View

The technique of standing axial radiographic imaging of the patellofemoral joint was introduced by Ahlback (1968). His device for support of the patella

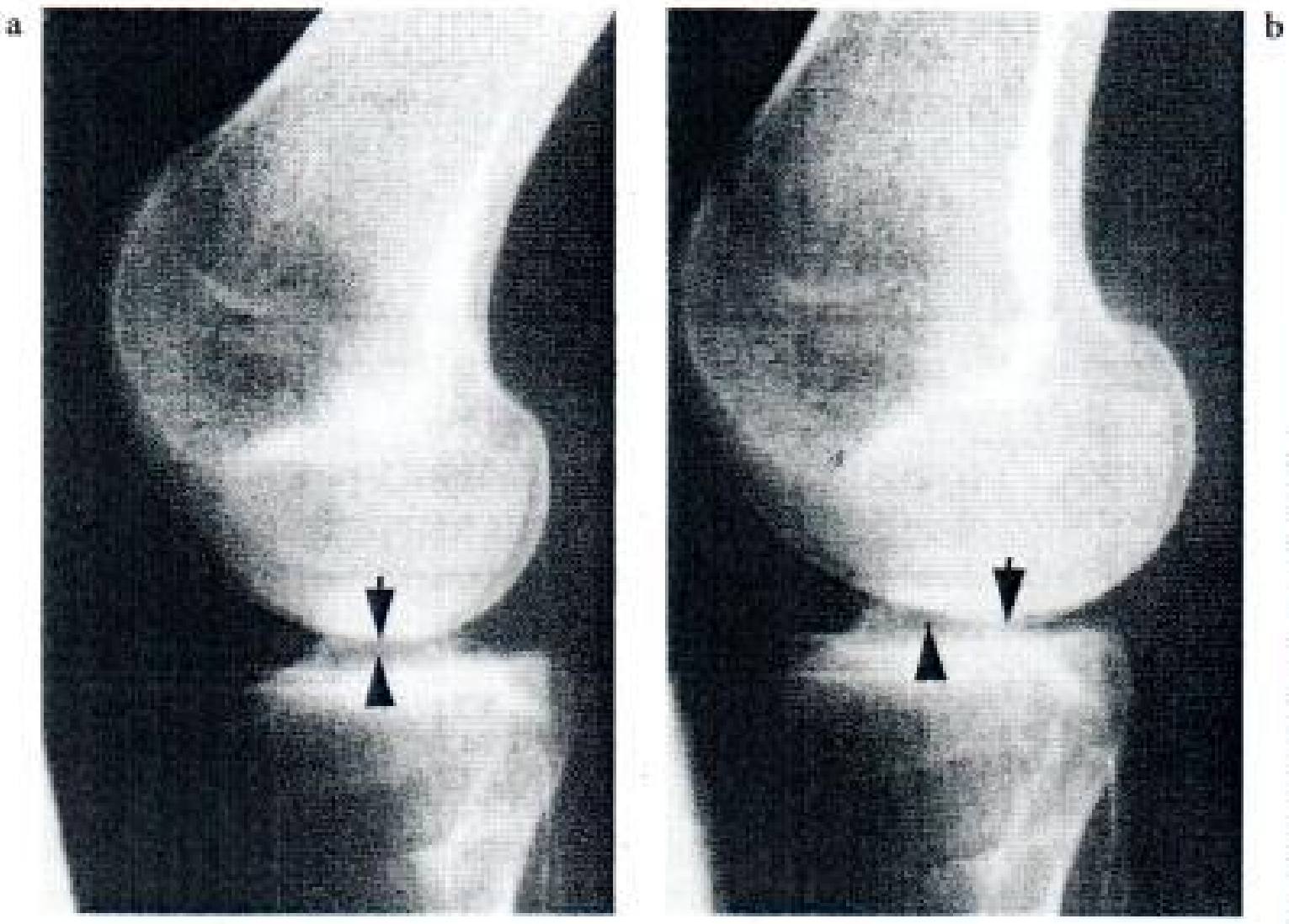

Fig. 13.13a, b. Lateral radiographic views of a 23-year-old female with rupture of the anterior cruciate ligament. Standing without loading (**a**) and at weight-bearing (**b**). Normally, in any degree of knee flexion, standing or supine, the lowest points of the articular surfaces of the femoral condyles (*arrow*) are sited at the center (*arrowhead*) of the tibial eminence (**a**). In weight-bearing (**b**) the tibia is displaced ventrally relative to the femur, indicating joint instability at every step of gait

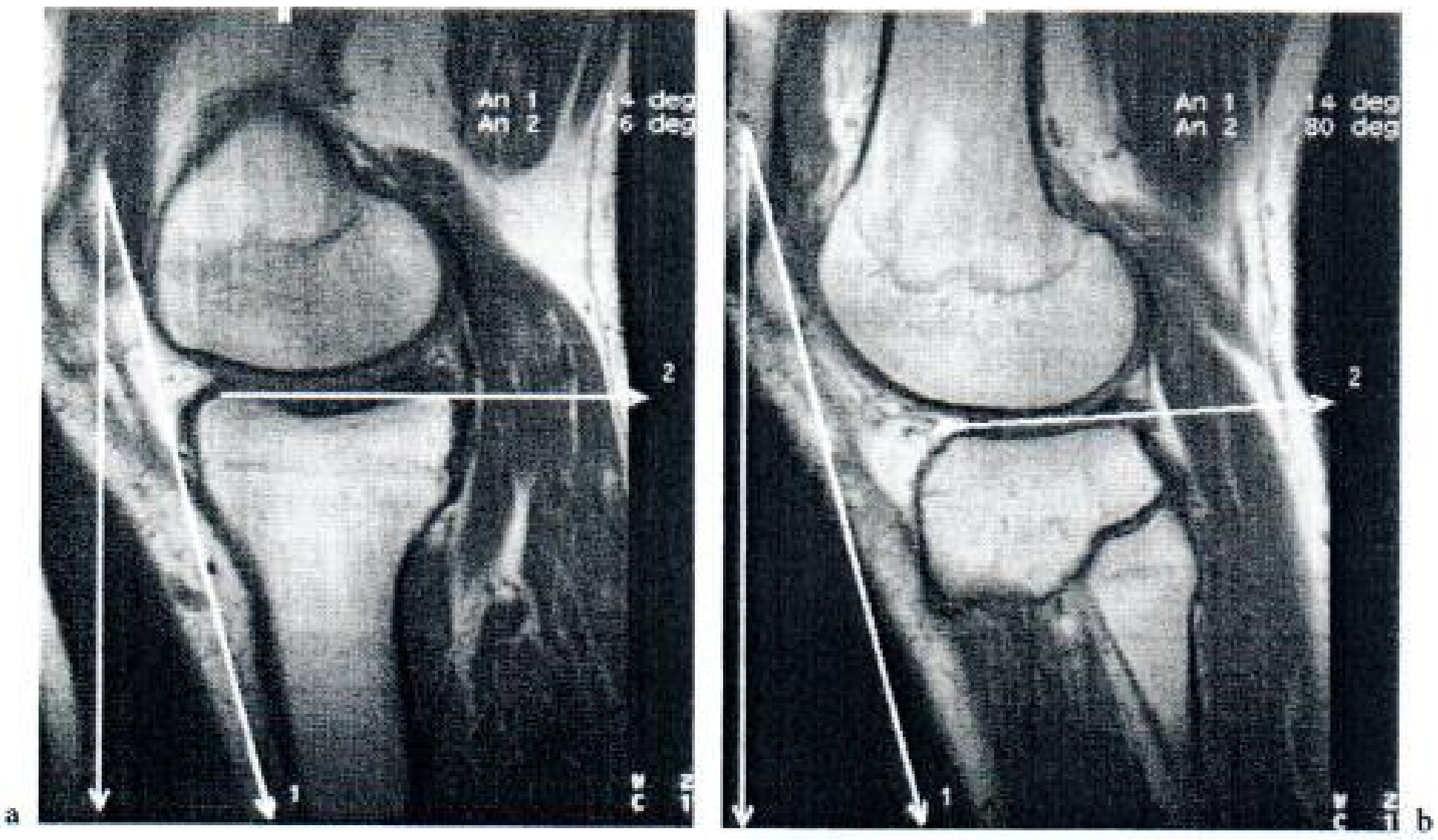

Fig. 13.14a, b. Sagittal T1-weighted MR images of the medial and lateral femoral and tibial condyles. The oblique line (*1*) is in a different image joining the anterior crest of the tibia. Relative to vertical (horizontal) the inclination of the tibia is 14°. The concave contour of the medial tibial condyles (**a**) is horizontal and thus has a dorsal slope of 14°. The orientation of the straight (commonly convex) contour of the lateral tibial condyle (**b**) is 4° less than that of the medial tibial condyle

Fig. 13.15. Anteroposterior radiographic view of a knee, with a normal difference of 4° in the slope of the medial and lateral femoral condyles in the sagittal plane. The view through the lateral joint space is tangential to the bony contour of the tibial condyle. Assessment of the medial joint space is hindered by both the anterior and the posterior aspect of the tibial condyle

during the examination is still widely used in Sweden, but it has been refined and the examination technique is more standardized (Egund 1986). Today we use the device shown in Fig. 13.16. Guided by the lateral view (Fig. 13.12), the inclination of the lower leg is adjusted to bring the articular surface of the patella into the vertical plane. There should be an even distribution of the body weight on both legs and knee flexion in our routine view is about 30°. The technique allows axial radiographs in different degrees of knee flexion between 20° and 100° (Fig. 13.17) without repositioning the knee relative to the device or changing the lower leg inclination (Egund 1986).

13.5.4
The Supine Axial View

Since Settegast (1921) recognized the axial view of the patellofemoral joint, various techniques (Fig. 13.18) have been described (Brattström 1964; Jaroschy 1924; Knutsson 1941), but the most simple and accepted techniques for routine and scientific purposes are those described by Merchant et al. (1974) and Laurin et al. (1979) (Figs. 13.18, 13.19). The Merchant technique as originally described required 45° of knee flexion and a specific cassette holder. By comparison, it was suggested that the method of Laurin be performed in 20° of knee flexion. Techniques with the beam directed from the ankle to the knee

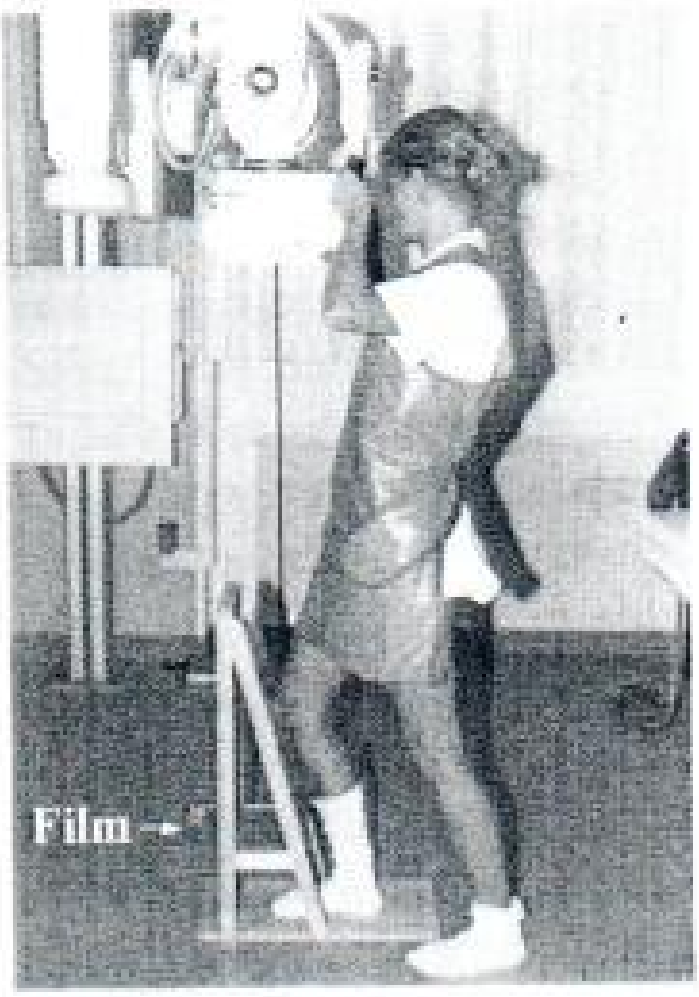

Fig. 13.16. Device for knee support and patient position for the axial, standing radiographic view of the patellofemoral joint. Relative to the position in Fig. 13.10, the inclination of the lower leg has been increased, with the foot placed more dorsally, which brings the articular surfaces of the patella in Fig. 13.12 into alignment with the vertical plane

(Bradley and Ominsky 1981; Laurin et al. 1979) and with the patient in the sitting position should be abandoned for radiation protection reasons. Both the Merchant and the Laurin technique, however, can be used in different degrees of knee flexion. In the supine position, the beams should be angled approximately 10° relative to the axis of the lower leg (Figs. 13.18, 13.19) in order to obtain images tangential to the patellar articular surface; this is because the patella has a lower position than in the standing position (Figs. 13.16, 13.32).

13.5.5
Radiographic Measurement of the Axis of the Knee

Total radiological evaluation of patellar tracking requires measurement of the long axis of the lower extremity, the HKA angle (hip-knee-ankle), and the Q angle as described by Sanfridsson et al. (2001b). These authors used the complicated QUESTOR Precision Radiography system (QPR) (Siu et al. 1991) for standardized and reproducible measurements in the standing position and reported a varying lack of correlation between clinical measurement of the Q angle in the supine position and radiographic measurement in the standing position. It appears from their results (Sanfridsson et al. 2001a) that the axis of the femoral shaft is reliable in the radiographic measure-

Fig. 13.17. Patient position to obtain the axial radiographic view with 90° of knee flexion

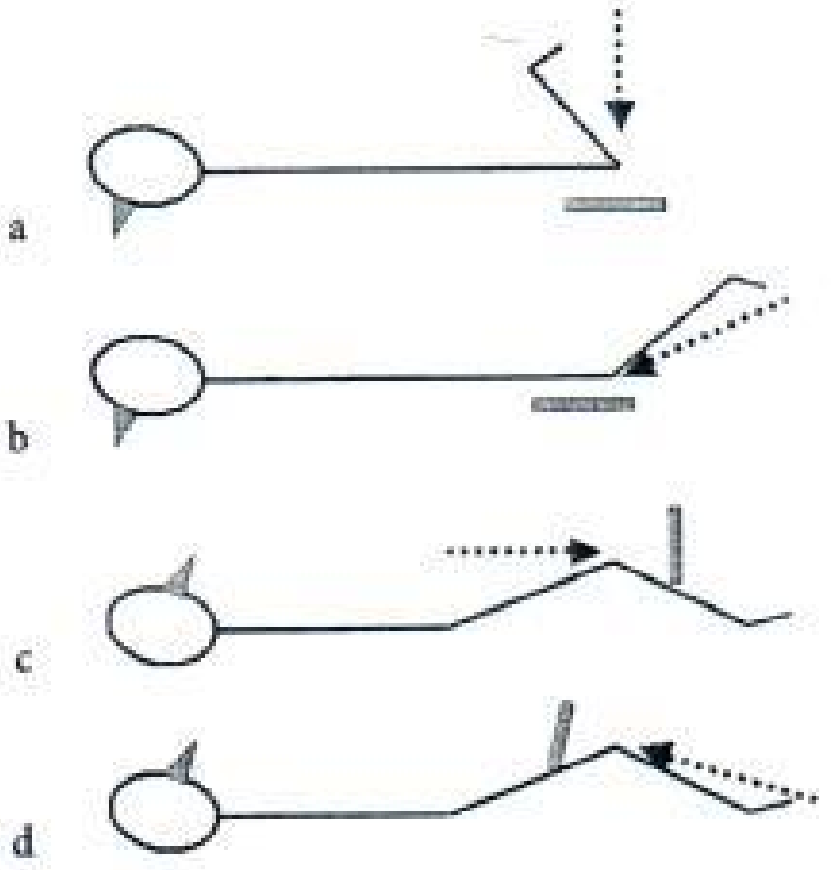

Fig. 13.18a–d. Different methods to obtain the axial radiographic view of the patellofemoral joint in the supine or prone position: a Settegast (1921); b Jaroschy (1924); c Knutsson (1941); d Laurin (1979)

Fig. 13.19. The Merchant et al. technique to obtain the axial radiographic view of the patellofemoral joint at 45° of knee flexion, commonly used in the United States. The technique requires a specific cassette holder. With both the Merchant and the Laurin technique, the beam direction relative to the tibia is less than 10°, whereas with the standing technique it is 15° (±6°)

ment of the Q angle, and therefore a true anteroposterior view of the knee in the standing position can be used for the measurement (Figs. 13.20, 13.21). The clinical significance of standing radiographic measurements of the Q angle requires further investigation.



Fig. 13.20. Biplane radiography of the knee supported by the device. A true lateral position of the femoral condyles is obtained at fluoroscopy using tube 1 and the image intensifier (*II*). A true anteroposterior view is obtained perpendicularly from tube 2. The film is placed in a cassette holder (*arrowhead*) also used for whole limb radiography

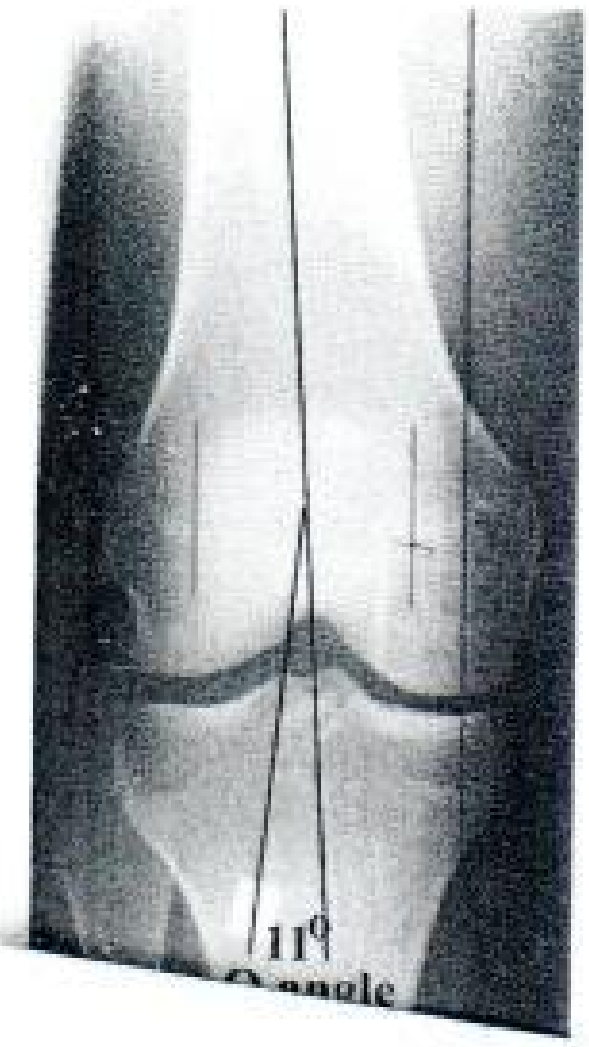

Fig. 13.21. Measurement of the
on a standing true
r radiograph of
° of flexion. The
sity was marked
lead

13.6 Roentgen Stereometric Analysis

Roentgen stereometric analysis (RSA) is a technique by which the relative motion of two objects, over time or before and after application of external or internal forces, can be assessed using rigid body kinematics. Since the skeleton consists of a number of rigid bodies, the method is particularly suited for skeletal radiology. It has gained increasing popularity in the assessment of joint replacement fixation (ÖNSTEN et al. 1993; KÄRRHOLM et al. 1994a; RYD et al. 1995) and fracture healing (KÄRRHOLM et al. 1983; AHL et al. 1988; RAGNARSSON et al. 1992). In the knee, in addition to the above uses, RSA has been applied to the anterior cruciate-deficient knee (KÄRRHOLM et al. 1988; FRIDEN et al. 1992) and in vitro examinations of the patellar joint (BLANKENVOORT et al. 1988).

RSA combines the principles of stereogrammetry, skeletal marking, and modern computing power into a system that allows measurement of motions down to at least 0.1° or 100 μm (RYD et al. 1986). The objects of interest are marked with balls made of tantalum. Tantalum is inert in body fluids and also heavy (atomic weight =73), and consequently yields distinct radiographic images. These markers should be placed in the objects of interest as far apart as the objects allow. A minimum of three markers in each object is required, but the insertion of five to seven markers in each increases the accuracy. Radiographic images are obtained in a stereo setting, i.e. two images are obtained simultaneously. A calibration object is also exposed, either before the patient is examined or, preferably, simultaneously with the patient examination. There are usually two set-ups available: a bi-planar set-up and a convergent-ray stereo set-up. In the former, the body part of interest, usually an arm or a leg, is placed inside a calibration box; two X-ray tubes at a right angle are positioned to expose films attached to adjacent sides of the calibration box, and frontal and lateral exposures are obtained. In the convergent ray alternative, X-ray tubes are aimed at approximately 40° from one another and films are exposed in the same plane underneath a calibration object, which, in turn, is situated underneath the tabletop carrying the patient. The two films, constituting a "stereo pair," are subsequently digitized and the x- and y-coordinates are fed into dedicated software to produce first a set of 3D coordinates for each patient marker and finally the kinematic analysis of how the two "rigid bodies," i.e., objects of interest (for example, the patella and the femur) have moved relative to one another.

RSA provides two advantages. First the accuracy is about one order of magnitude better than conventional radiography, and second, the system allows perfect characterization of the motion in all 6 degrees of freedom of motion. Hence, "out-of-plane" motion can also be analysed.

RSA has not previously been utilized in connection with patellar motion proper. Blankenvoort et al. (1988) used it to study the screw-home mechanism, which is inherently involved in the complex motions of the patella. They found that the screw-home motion is a facultative occurrence, dependent on how the femur and the tibia are positioned rotationally relative to one another at an initial point in time. Similarly, Kärrholm and co-workers have published a number of reports on the kinematics of the knee, including rotational motion between the femur and the tibia (Kärrholm et al. 1994b; Uvehammer et al. 2000). In general they have found that femorotibial rotation is less in an artificial knee than in the normal one. The potential of RSA has not yet been fully realized with regard to the patellar joint, although studies are in progress in Lund on patients in whom all three bones (femur, tibia, and patella) have been marked.

13.7
CT and MR Imaging of Patellar Tracking

Transaxial imaging of the patellofemoral joint by CT and MR imaging allows assessment of the position of the patella above and within the femoral trochlea over a range of extension and mild flexion of the knee which is inaccessible for radiographic examination in the axial plane (Figs. 13.27, 13.28). The rationale for viewing the patellofemoral relationship in mild flexion is based on the fact that most patellar subluxations and dislocations occur within the first 20°–30° of flexion. Static CT and MR imaging can be used to obtain axial images at defined degrees of flexion with and without contraction of the quadriceps muscle (Delgado-Martins 1979; Martinez et al. 1983b). Assessment of patellar tracking by kinematic CT and MR imaging has been extensively reported (McNally et al. 2000; Dupuy et al. 1997; Shellock et al. 1989; Brossmann et al. 1993, 1994) with and without active loading during flexion to extension, and a number of devices have been developed for these purposes.

13.7.1
Measurements

Vertical patellar height is important for the biomechanics and stability of the extensor mechanism and patellofemoral joint. Measurements are performed on the lateral radiographic view in at least 30° of flexion, at which the patellar tendon is considered under tension in the supine position, although this has not been documented. We perform all measurements of patellar height from lateral standing views at more than 20° of flexion. The most widely employed method for assessing patellar height has been described by Insall and Salvarti (1971) and is based on the length of the patellar tendon divided by the greatest diagonal length of the patella (Fig. 13.22a). The normal ratio is 1.02 with an SD of 0.13. A ratio of

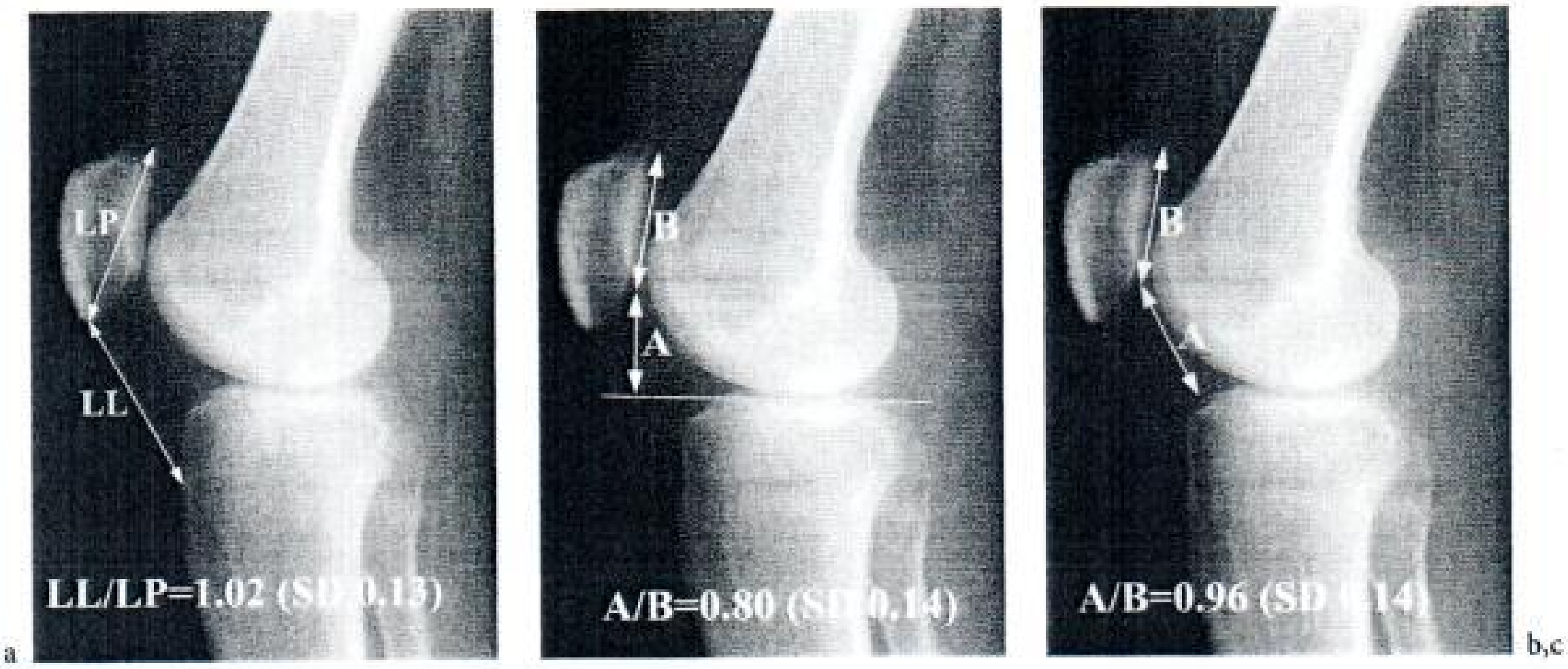

Fig. 13.22a–c. The most common methods of measuring patellar height: **a** Insall and Salvarti (1971); **b** Blackburne and Peel (1977); **c** Caton et al. (1982). LL, Length of the patellar tendon; *LP*, maximum diagonal length of the patella

less than 0.80 is considered indicative of patella baja and a ratio of greater than 1.20 as indicative of patella alta. The Insall-Salvarti index may give an inaccurate impression of patellar height relative to the femoral condyles owing to anatomical variations in the length of the patella and the position of the tibial tuberosity (Grelsamer and Meadows 1992); this is especially so following transfer of the tibial tuberosity.

To assess patellar height, Blackburne and Peel (1977) divided the perpendicular distance from the lower margin of the patellar articular surface to the line joining the tibial plateau by the length of the articular surface of the patella (Fig. 13.22b). The normal ratio was 0.80 with an SD of 0.14. It is generally considered that, compared with the Insall-Salvarti index, this method provides a more reliable measure of patellar height relative to the femoral trochlea, with less interobserver variability (Seil et al. 2000); furthermore, it has also been adopted in orthopedic research. The method described by Caton et al. (1982) represents a similar measurement of patellar height (Fig. 13.22c). The vertical position of the patella has been assessed relative to a line drawn through the distal femoral condyles and perpendicular to the long axis of the tibia, thereby avoiding the potential confounding variations in the inclination of the tibial plateau (Egund et al. 1988). This measurement was expressed relative to body height and has a very high correlation to the Blackburne and Peel index.

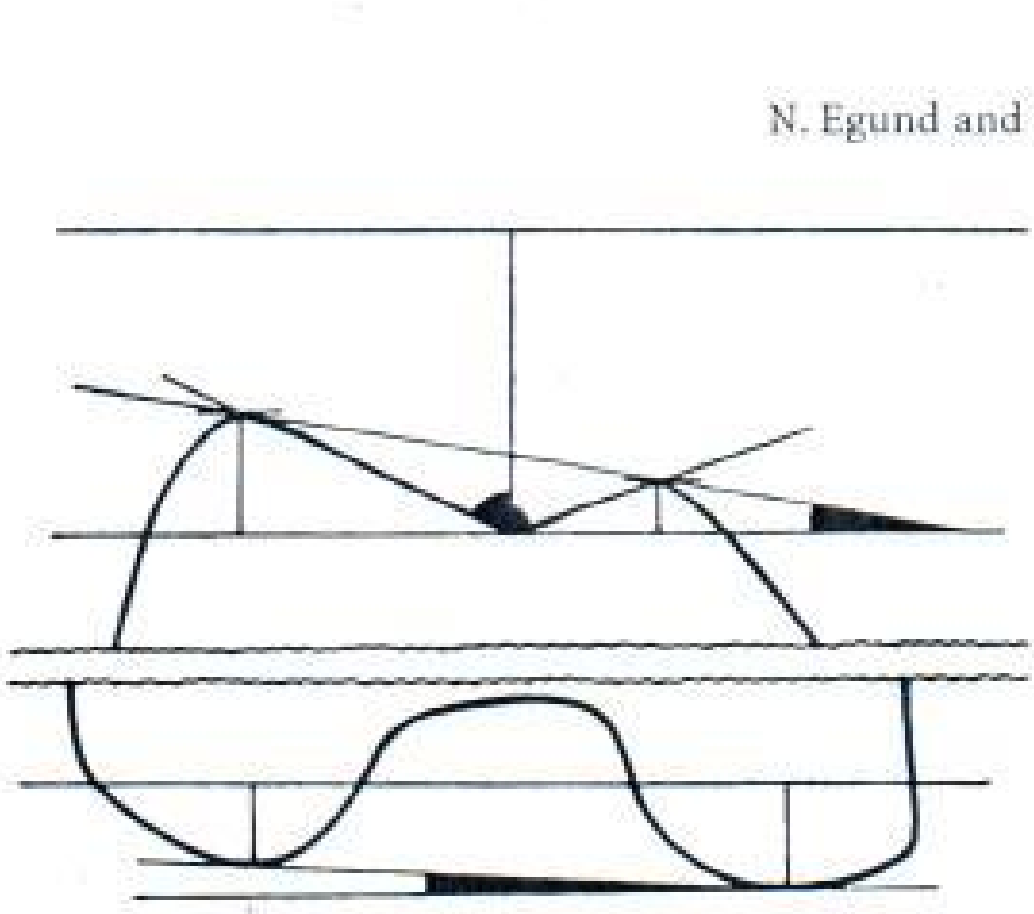

Fig. 13.23. The radiographic measurements of the patellofemoral joint performed by Brattström (1964) obtained with high radiation doses to the patient from two complicated projections of the anterior and posterior aspect of the femoral condyles

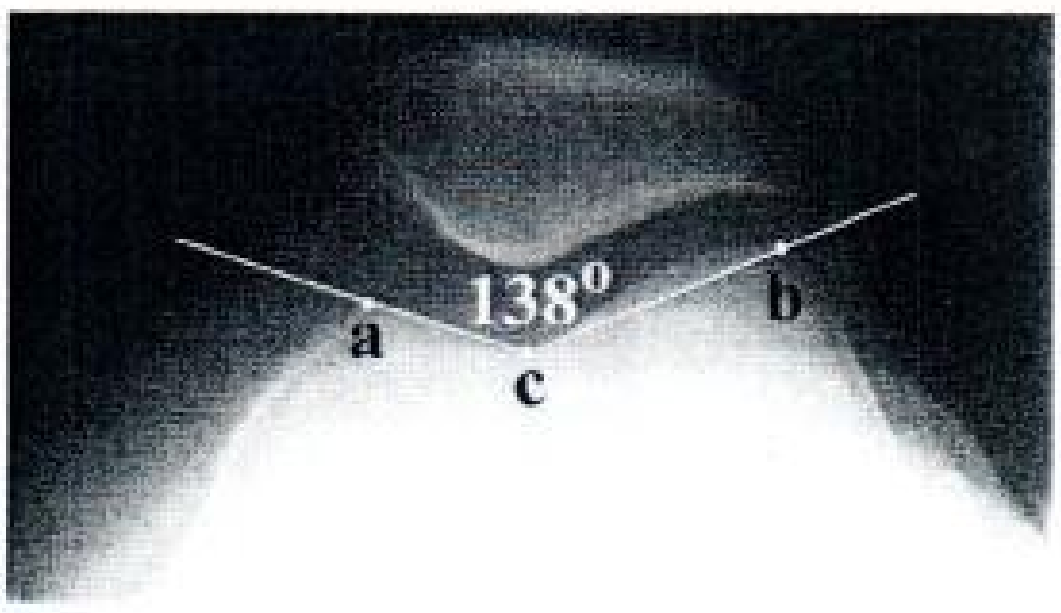

Fig. 13.24. Measurements of the sulcus angle according to Brattström (with personal communication). *a*, Medial border of the bony articular surface; *b*, arbitrary landmark close to the lateral border of the articular surface; *c*, lowest point of the intercondylar sulcus

13.7.2
The Femoral Trochlea and Patellar Tracking

The classical work by means of radiography on the configuration of the femoral condyles is that of Brattström (1964), who investigated the angles and distances of the femoral trochlea relative to the coronal plane of the dorsal aspect of the femoral condyles (Figs. 13.23, 13.24). The normal *sulcus angle* of 142° (SD ±0.6° with no significant right/left or sex differences) was obtained from radiographs of the femoral trochlea at an angle of approximately 25° between the beam and the longitudinal axis of the femur. With reversed direction of the beam, Merchant et al. (1974) obtained similar measurements with respect to the sulcus angle, 138° (SD±6°, range 126°–150°), and found no significant change in the shape of the trochlea through the range of beam to femur angles from 15° to 75°. In patients with uni- or bilateral patellar displacement, the sulcus angle may be increased to above 150° with no significant right/left differences (Brattström 1964).

The *congruence angle*, which measures the relationship of the V-shaped patellar articular ridge to the groove of the femoral trochlea (Fig. 13.25), was introduced by Merchant et al. (1974). They suggested that any congruence angle greater that +16° is abnormal and may indicate lateral instability of the patella. Another measure of patellar tracking, that might be appropriate, is *the lateral patellofemoral angle* (Laurin et al. 1978, 1979). On axial radiographs, normally an angle formed between a line connecting the anterior aspects of the femoral condyles and a second line joining the lateral facets of the patella opens laterally (Fig. 13.26). In all their 30 patients with recurrent subluxation, these lines were either parallel or opened medially, but the lines were normal in 90% of patients with chondromalacia. Laurin et al. (1979) also introduced a mea-

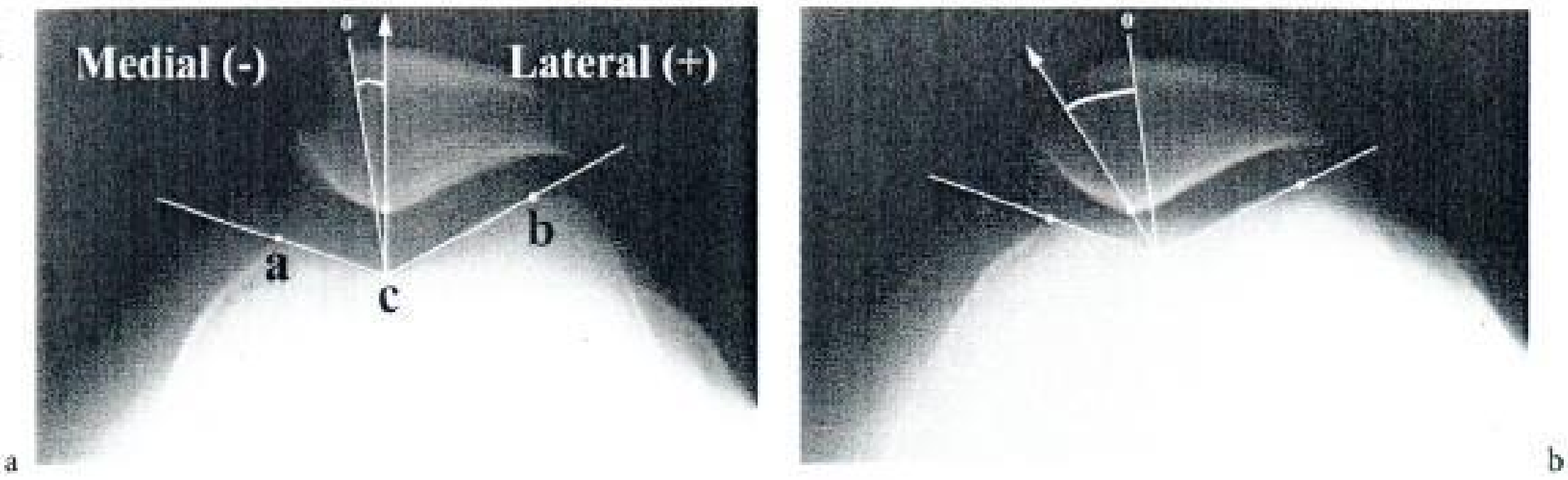

Fig. 13.25. Measurement of the congruence angle according to MERCHANT et al. (1974), with **a** the supine (LAURIN) and **b** the standing examination technique in the same normal knee. The landmarks *a* and *c* are the same as in Fig. 13.24, and *b* represents the highest point of the lateral condyle. *Line O* bisects the sulcus angle and the *arrow line* joins the lowest point of the articular ridge of the patella (d) (not marked on figure). There is an obvious medial displacement of the patella between figure parts **a** and **b**, but minor differences in the position of (d) will influence the angle measurement

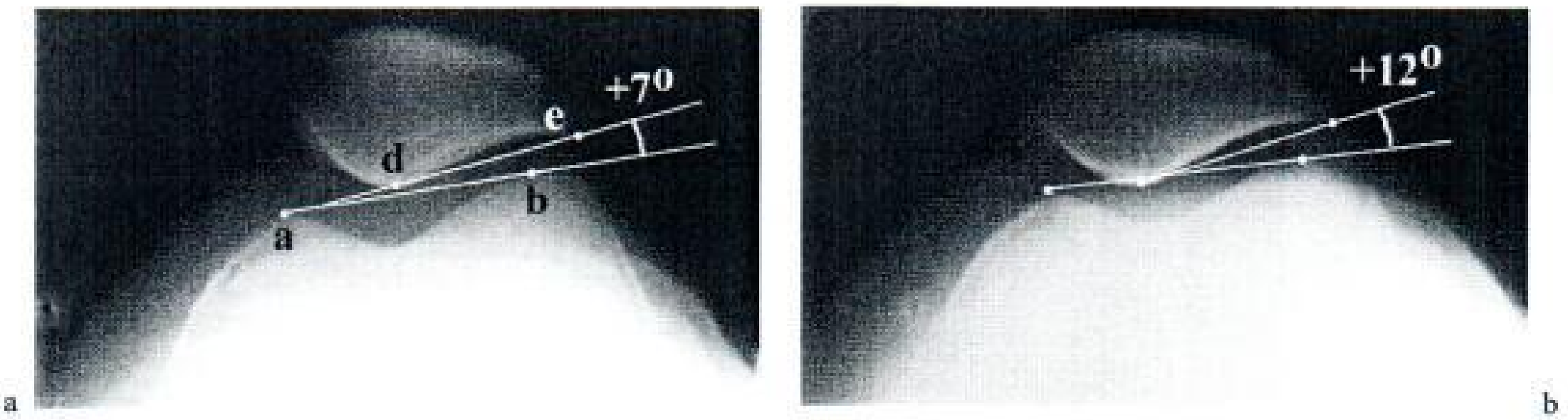

Fig. 13.26. Measurements of the normal lateral patellofemoral angle according to LAURIN et al. (1978, 1979), with **a** the supine and **b** the standing examination technique. The *line a–b* joins the highest points of the femoral condyles and *line d–e* the lateral articular surface of the patella. It appears that point *b* does not correspond to point *e*. Angles of 0° or with medial opening (-) are abnormal and indicate lateral tilt

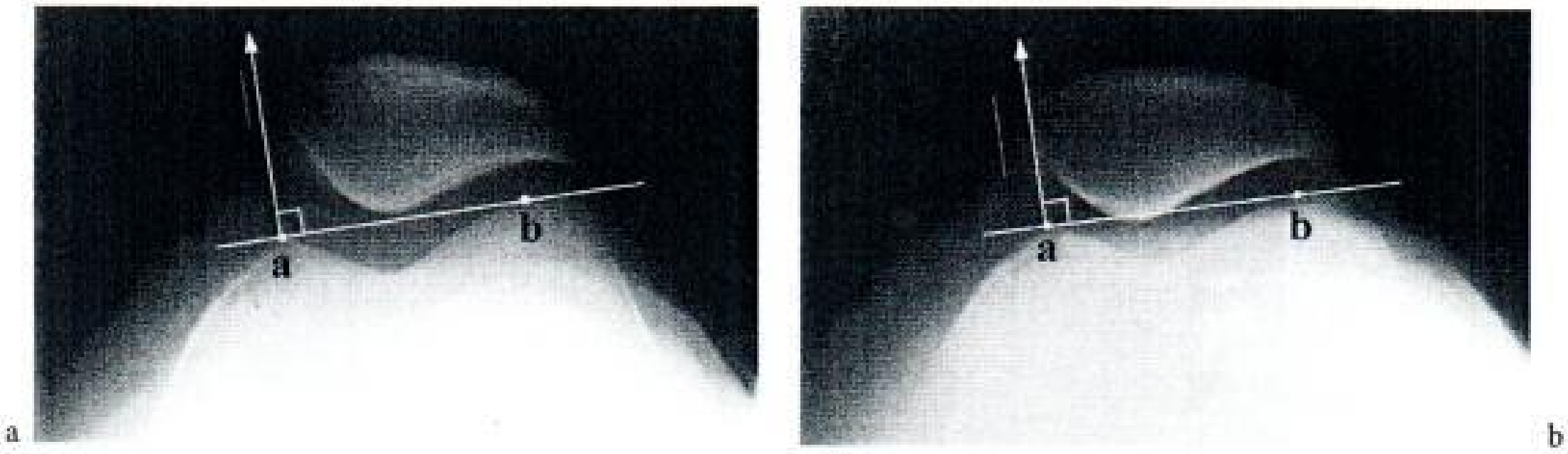

Fig. 13.27a, b. Measurement of medial-lateral patellar displacement according to LAURIN et al. (1979). **a** and **b** are obtained in the supine and the standing position, respectively. Patellar displacement is measured as the distance in millimeters between the *arrow line* drawn 90° to *line a–b* and the medial edge of the patella. The width between points *a* and *b* varies with the angle of tangency of the beam to the femoral condyles and between individuals

sure of lateral patellar displacement (Fig. 13.27). The congruence angle, the lateral patellofemoral angle, and measurement of lateral patellar displacement have all been used frequently in the assessment of patellar instability by means of CT and MR imaging (DUPUY et al. 1997; MCNALLY et al. 2000; BROSSMANN et al. 1993). Direct and oblique transaxial imaging of the femoral condyles by CT and MR imaging allows assessment of the transverse axes and lateral articular surface of the patella relative to the plane of the posterior femoral condyles (Figs. 13.28, 13.29), which is considered a reliable reference plane (Schutzer et al. 1986; Brossmann et al. 1993, 1994).

The position of the tibial tuberosity relative to the sagittal plane through the sulcus of the femoral trochlea (Fig. 13.30) has been measured by CT and MR imaging in individuals with normal patellar tracking and in patients with patellar instability (Ando et al. 1993; Muneta et al. 1994; Beaconsfield et al. 1994; Jones et al. 1995; McNally et al. 2000). The consistency of the results indicates that a distance exceeding 20 mm may be indicative of severe maltracking. Using a metal marker on the tibial tuberosity and axial radiographic views, Nagamine et al. (1999) demonstrated an abnormal lateral position of the tibial tuberosity in patients with lateral patellofemoral arthrosis in 30° of flexion, and in comparison with CT, the abnormal lateral position of the tibial tuberosity remained unchanged at extension (Nagamine et al. 1997).

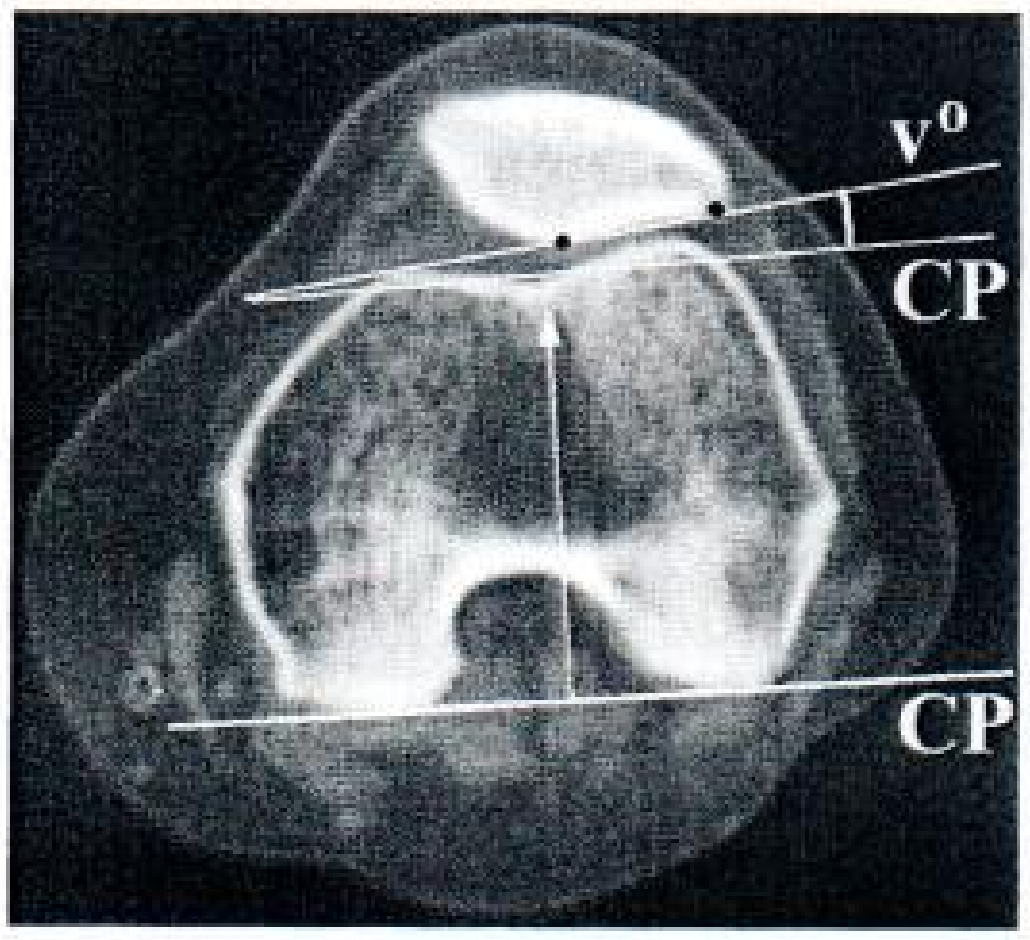

Fig. 13.28. Measurement at CT of the lateral patellofemoral angle (v°)relative to the femoral condylar plane (*CP*)

Axial radiographic views in the standing weight-bearing position (Ahlbäck 1968; Egund 1986) have been used widely in clinical studies in Sweden and also in the assessment of the degenerative patellofemoral joint in comparison with MR imaging (Boegaard et al. 1998c). Axial radiographic views obtained in both the standing and the supine position were compared in 111 knees in 57 patients (Egund 2001). In 39 knees with no change in patellar shift there was a mean lateral tilt of 3° from standing to supine, and in 33 knees with both lateral shift and tilt in the supine position, the patella returned to complete alignment in the standing position (Figs. 13.25–13.27, 13.39). Also in the standing position and extension or slight knee flexion any lateral patellar displacement observed at supine imaging is nullified (Fig. 13.31) (Egund et al. 2001). Optimal axial radiographic views with the direction of the beams tangential to the patellar joint surface were obtained in the standing position at 15° of inclination of the lower leg (Egund 1986), but the angle had to be decreased in most examinations in the supine position. This indicates that patellar height and patellofemoral contact areas are different in the standing and the supine position (Fig. 13.32). Also, the

Fig. 13.29a, b. Measurement at CT of lateral patellar displacement according to Brossmann et al. a Bisect offset is percentage, *a/b* + 100, of patella lateral to the projected perpendicular line. b Similar to the measurements of Laurin et al. (Fig. 13.27)

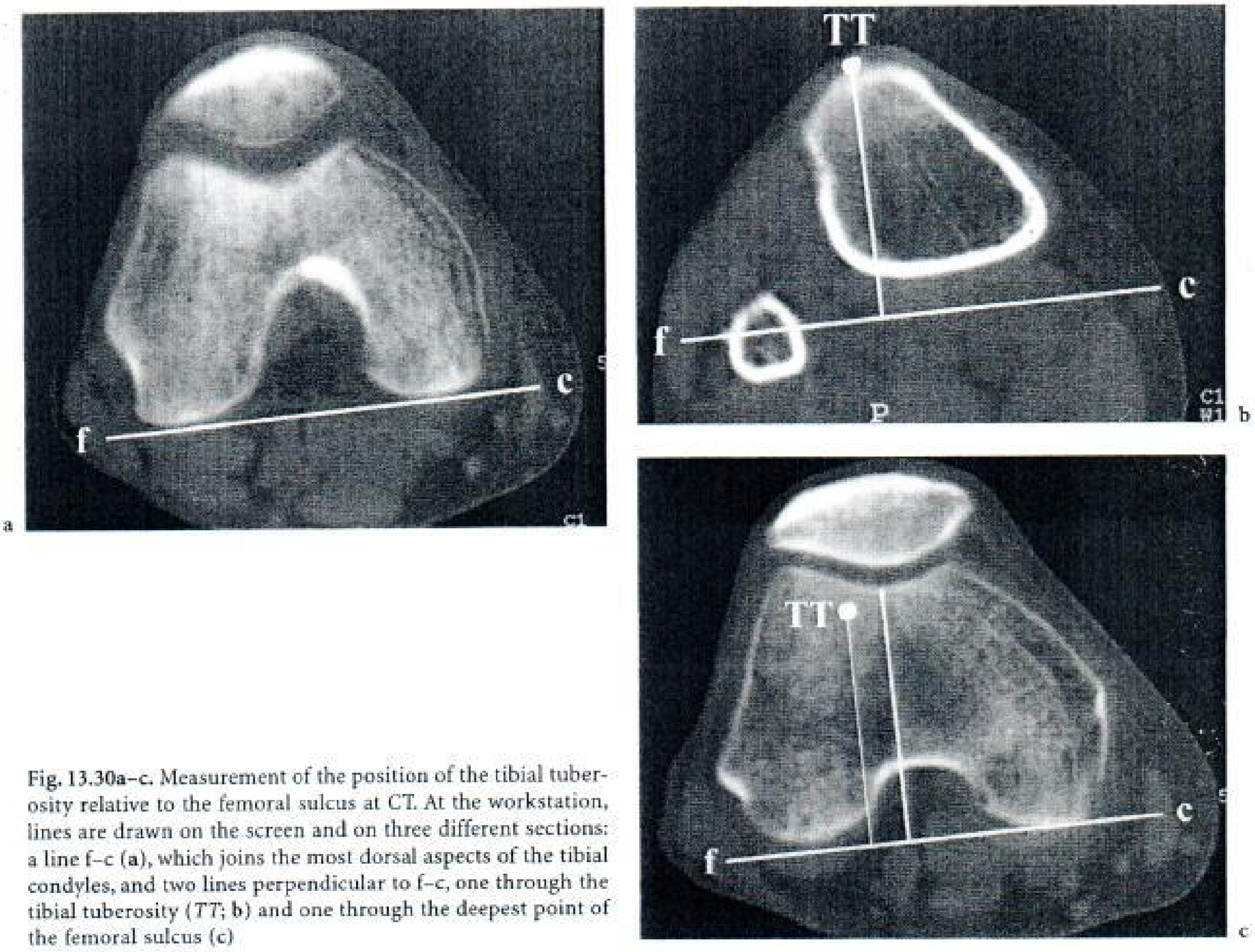

Fig. 13.30a–c. Measurement of the position of the tibial tuberosity relative to the femoral sulcus at CT. At the workstation, lines are drawn on the screen and on three different sections: a line f–c (**a**), which joins the most dorsal aspects of the tibial condyles, and two lines perpendicular to f–c, one through the tibial tuberosity (*TT*; **b**) and one through the deepest point of the femoral sulcus (**c**)

examination technique used may influence femorotibial rotation (Fig. 13.32) and thus the position of the tibial tuberosity relative to the femoral trochlea.

13.7.3
Summary of Radiological Measures of Patellar Tracking

The results reported in the literature on normal patellar motion are still inconsistent, but in general the original results and thoughts of Laurin et al. (1978) and Merchant et al. (1974) have been confirmed by means of CT and MR imaging.

In the *non-loaded, supine position* and in asymptomatic knees, at 30° of knee flexion and with relaxed quadriceps muscles, the articular surfaces of the patella are aligned with those of the femoral trochlea, but in some subjects there is a slight tendency towards lateral tilting and displacement. Between 20° of flexion and complete extension there is an increased tendency towards lateral shift and displacement. Lateral displacement and tilt may both be reduced (Dupuy et al. 1997) or increased (Brossmann et al. 1994) during active quadriceps function.

In normal subjects, the tibial tuberosity is positioned lateral to the sagittal plane through the deepest point of the femoral trochlea at a distance of less than 20 mm (Beaconsfield et al. 1994), and in most patients with maltracking this distance is more than 20 mm (Jones et al. 1995; McNally et al. 2000).

In the weight-bearing position, the axial radiographic view of normal subjects in the standing position always shows alignment between the medial and lateral joint surfaces of the patellofemoral joint (Egund 2001), and this is also true in those with lateral tilt and displacement when examination is performed in the supine position (Figs. 13.25, 13.31). During walking the excursion of the patella is medial rather than lateral (Stein et al. 1993). Between flexion and full extension when standing on both legs there is an outward rotation of the tibia relative to the femur of 5° (Sanfrids-

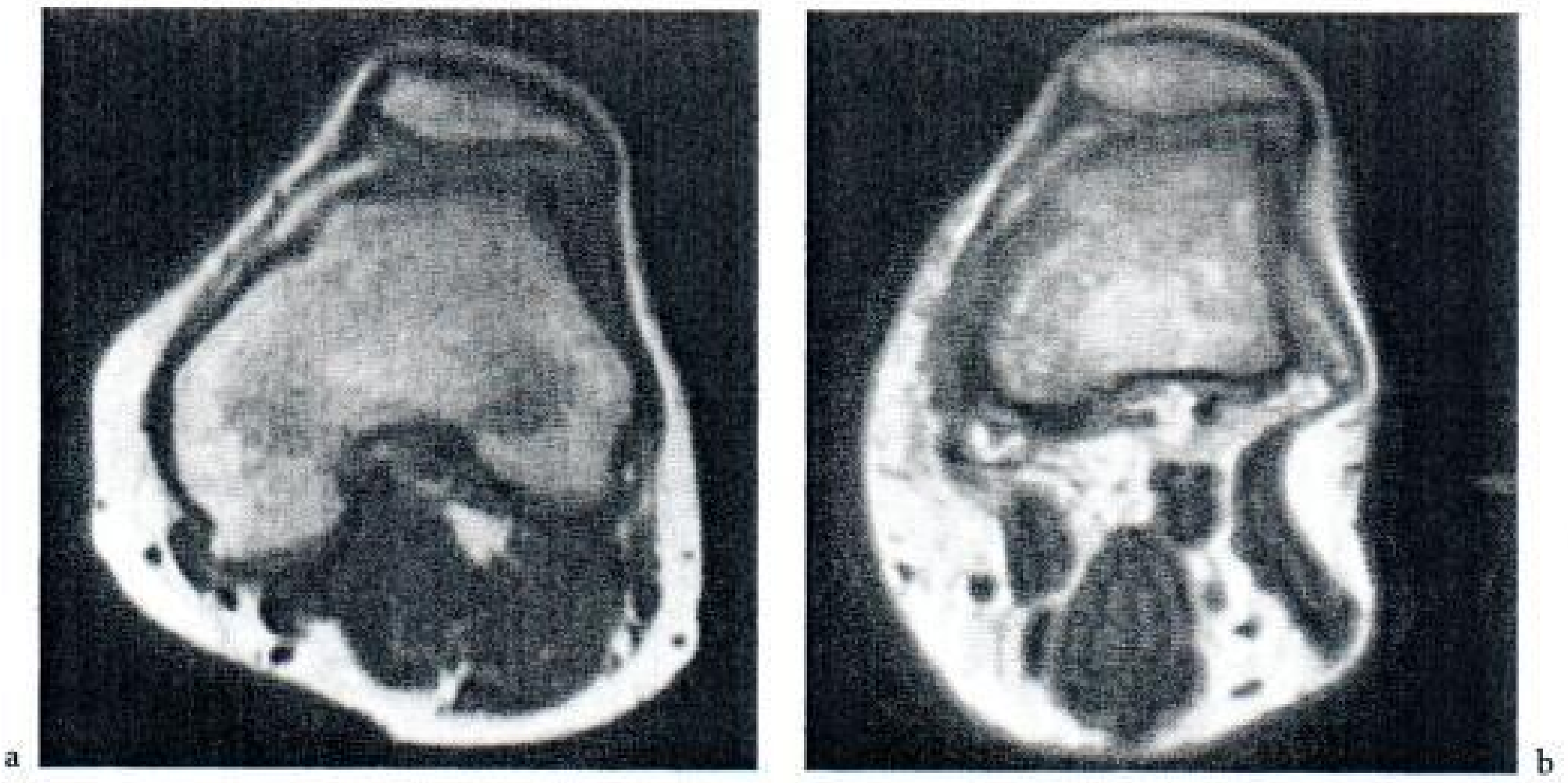

Fig. 13.31. Transaxial MR images of a 28-year-old male with patellar instability, obtained a supine at 10° of knee flexion and b standing, with weight-bearing at extension. The normal lateral patellar displacement in the supine position (a) does not occur in the standing position, even at extension (b)

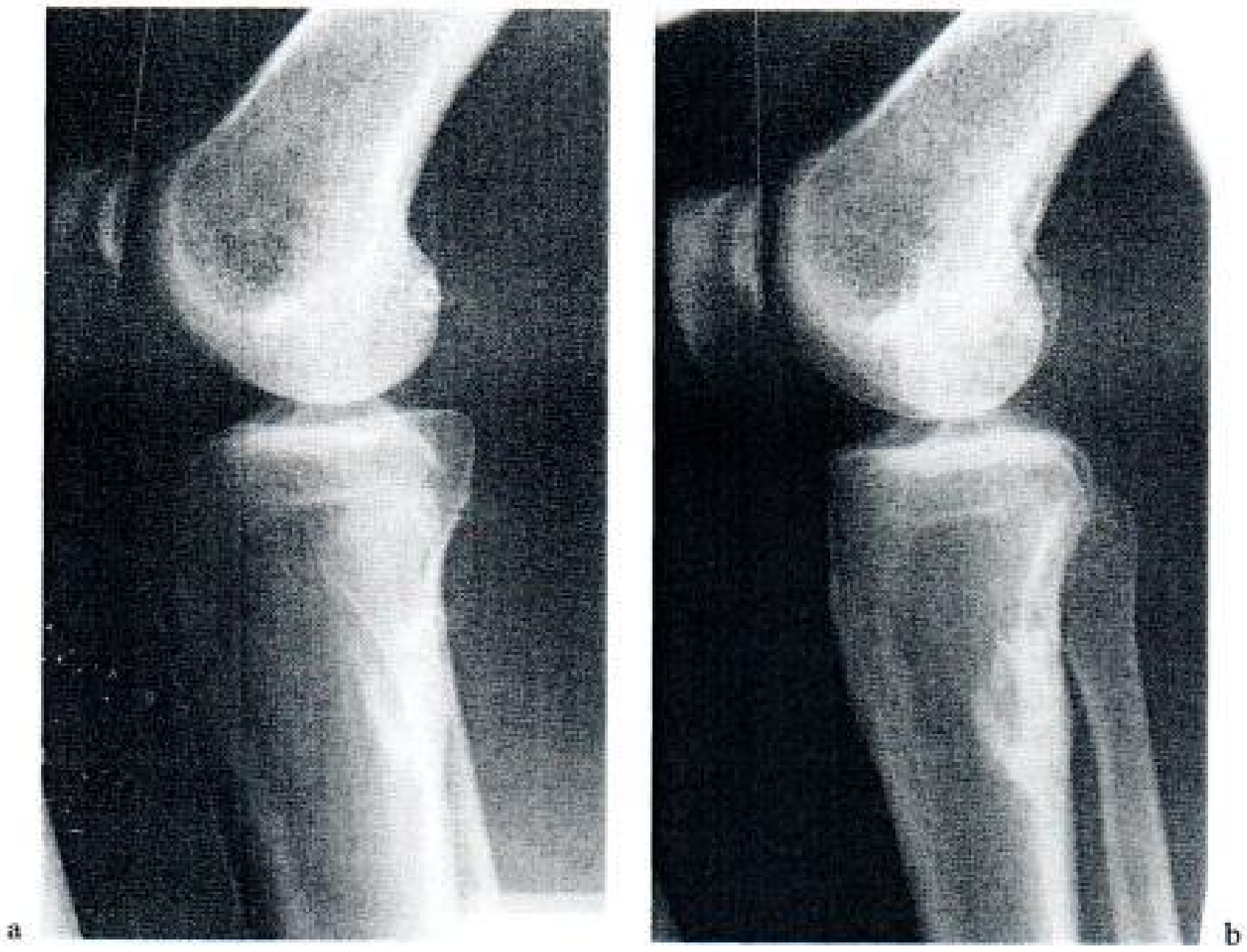

Fig. 13.32. a Standing, lateral radiographic view of a knee controlled for tibial cortical sclerosis. The distal portion of the tibia is not in contact with the plate of the device (see Fig. 13.12) and the tibial plateau is not horizontal. Knee flexion is too high for the anteroposterior view. b A previous lateral view obtained in the supine position. Femoral rotation is almost identical in a and b, but there is a large difference in tibial rotation, indicated by the position of the fibula. Also there is a large difference in the position of the patella between standing (a) and supine (b), as regards both the vertical height and the articular surface orientation (*gray line*) relative to the tibial surface

son et al. 2001b), which may not occur in the non-loaded knee (Blankevoort et al. 1988).

In conclusion, as previously suggested by Stein et al. (1993), standing examination is to be considered the "state of the art" technique for the assessment of patellar tracking. Visualization of the function, performance and biomechanics of the knee is inadequate when using supine imaging, including arthroscopy. There is consequently a need to reevaluate conclusions drawn without the use of views obtained in the

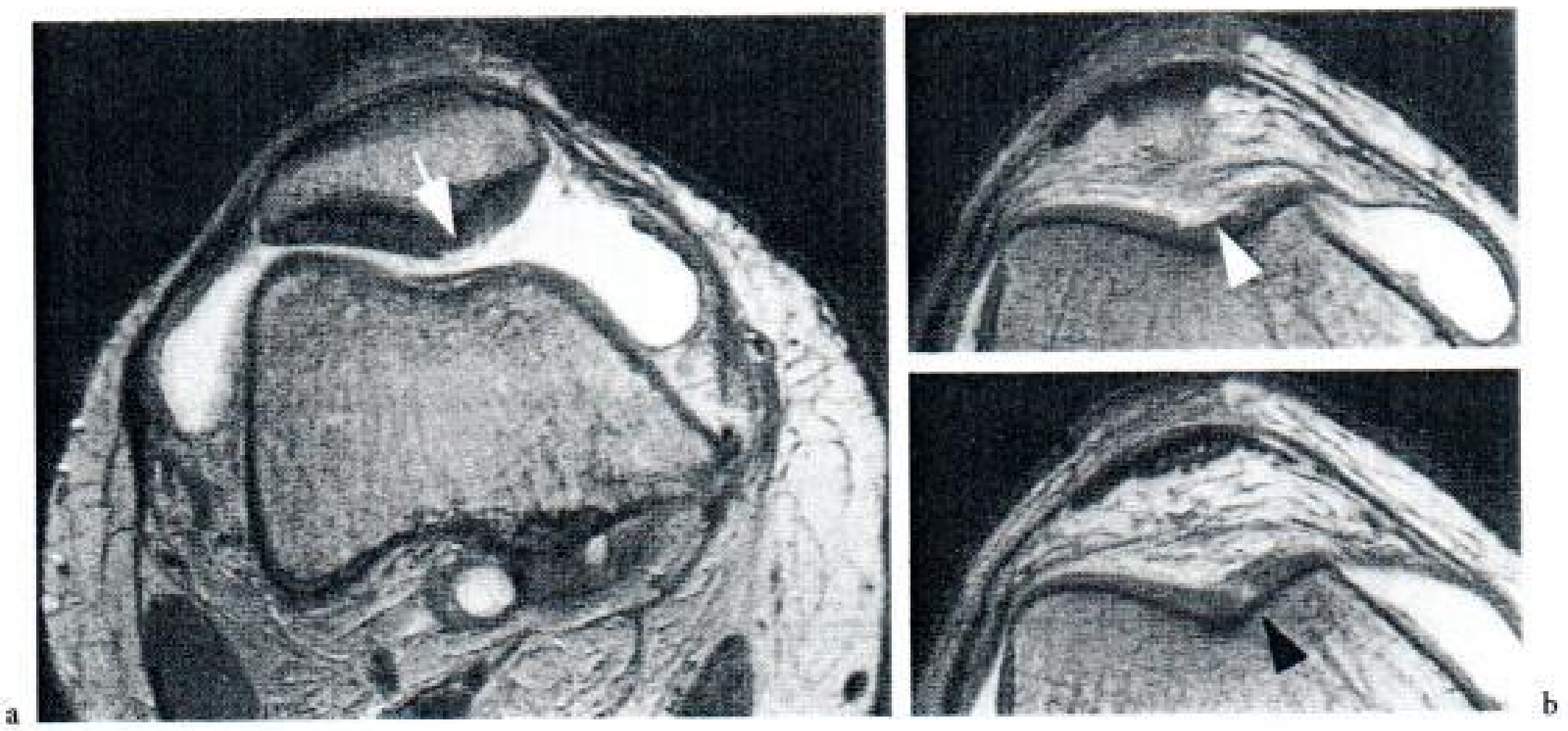

Fig. 13.34a, b. Transaxial MR images of the knee of the same patient as in Fig. 13.33. In the patella (*arrow*) and the femoral condyle (*white arrowhead*) there are superficial cartilage defects and in another section fissuring of the cartilage to the subchondral bone (*black arrowhead*). Even small cartilaginous lesion can be demonstrated with this proton fat-saturated sequence

Table 13.2. Grading system for the knee joint employed by the authors

Feature	Grade	Definition	Compartment			
			Femorotibial		Patellofemoral	
			Medial	Lateral	Medial	Lateral
Joint space narrowing	0	None	☐	☐	☐	☐
	0.5	25% joint space narrowing	☐	☐	☐	☐
	1	50% joint space narrowing	☐	☐	☐	☐
	1.5	75% joint space narrowing	☐	☐	☐	☐
	2	100% joint space narrowing	☐	☐	☐	☐
	3	<5 mm attrition	☐	☐	☐	☐
	4	5–10 mm attrition	☐	☐	☐	☐
Osteophytes	0	None				
	1	Small (definite) osteophytes				
	2	Moderate osteophytes				
	3	Large osteophytes				
Subchondral sclerosis	0	Absent				
	1	Present				
Sharpening of tibial spine	0	Absent				
	1	Present				
Chondrocalcinosis	0	Absent				
	1	Present				
Osteonecrosis	0	Absent				
	1	Present				

(1957) grading system concerns the question of whether or not marginal osteophytes (Spector and Hochberg 1994; Brandt et al. 1991) represent definitive evidence of cartilage degeneration (Boegard et al. 1998a): this is a subject which can still unite or divide radiologists. Marginal osteophytes appear as a sign of bony reaction at sites where articular cartilage is continuous with the synovial membrane and periosteum (Resnick and Niwayama 1995). The sites of marginal osteophytes are most commonly far away from the focal cartilaginous lesion of OA. Their presence should be considered a sign of processes in the synovium and surrounding soft tissue which may react to mediators of cartilage damage and repair (Edwards 1998; van den Berg et al. 1998).

13.8.1
Imaging of Patellofemoral Osteoarthrosis

Given that both isolated and combined femorotibial and patellofemoral OA may occur, the routine radiographic examination for the diagnosis of OA of the knee joint should always comprise weight-bearing AP and lateral views of the knee as well as transaxial views of the patellofemoral joint (Fig. 13.12). The axial radiographic view obtained in the supine position may only occasionally demonstrate medial patellofemoral OA (Figs. 13.35–13.37); furthermore, lateral patellofemoral OA may occasionally be missed in the supine position although it is visible with the standing technique (Egund 2001). Medial and lateral patellofemoral OA is commonly associated with medial and lateral displacement of the patella, respectively, and therefore imaging in the supine position may not demonstrate the condition of the joint space of the other facet (Fig. 13.38). It may be necessary to perform a standing examination in different degrees of knee flexion to visualize both patellofemoral and femorotibial OA.

A common reason for admission is the need to perform MR imaging for the diagnosis of early OA of the patellofemoral joint when joint spaces are normal in all three compartments on standing radiographs.

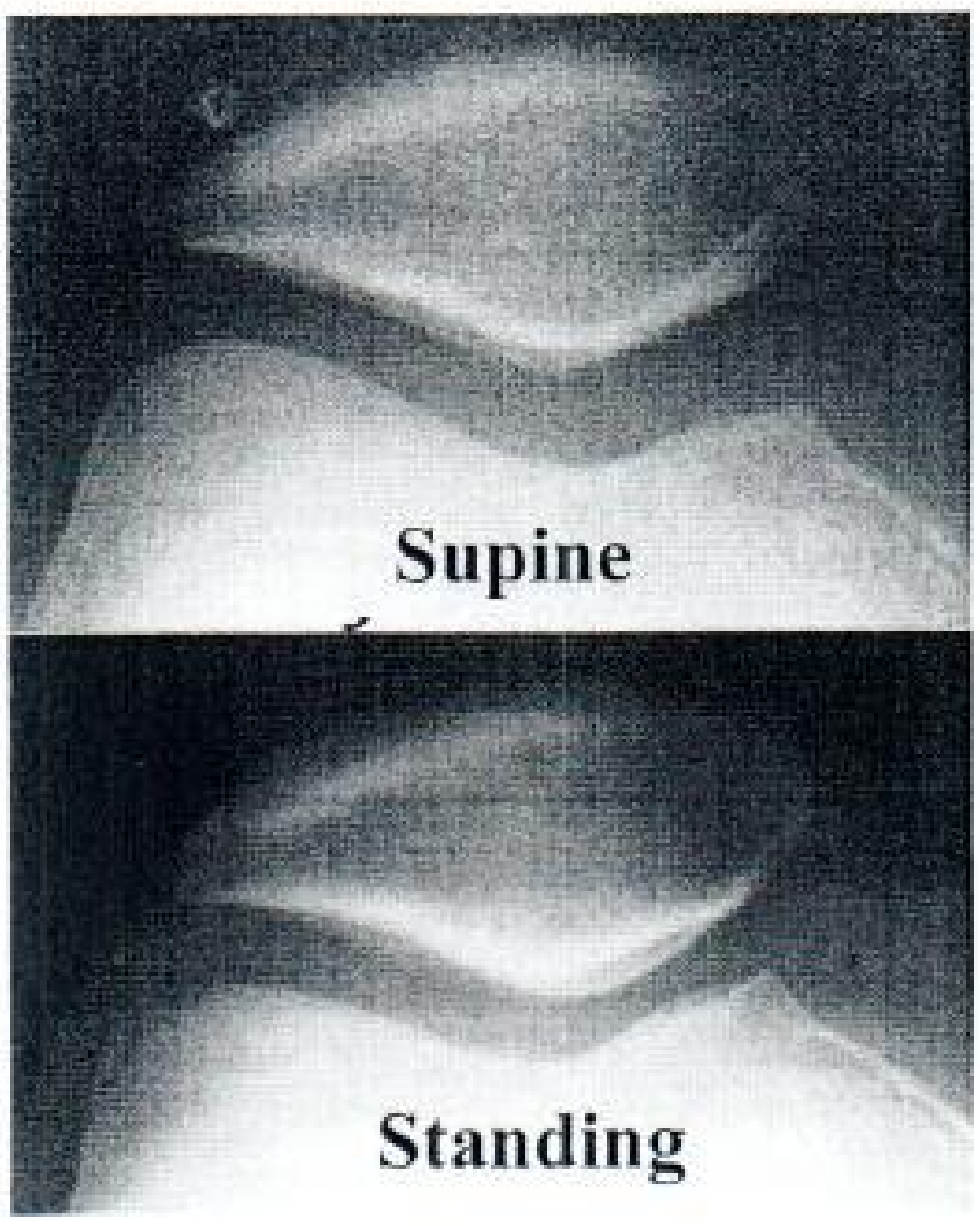

Fig. 13.35. Axial radiographic views obtained in the supine and standing positions in a 48-year-old female with anterior knee pain. Arthrosis suspected from the slight joint space reduction visible only on the standing examination was confirmed at MR imaging

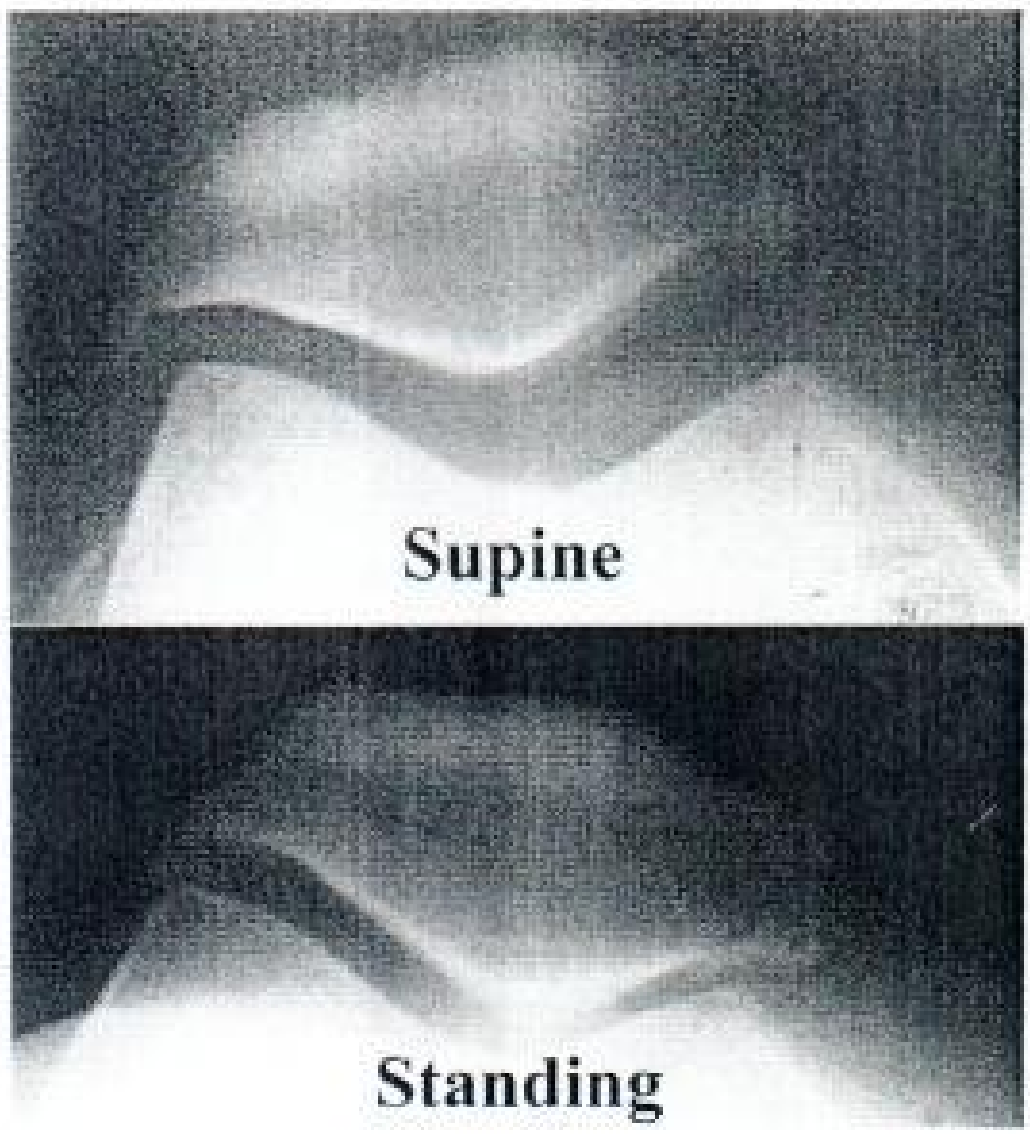

Fig. 13.36. Axial radiographic views obtained in the supine and standing positions in a 51-year-old male with anterior knee pain. A 75% reduction (stage 1.5) of the medial joint space could only be demonstrated by the standing examination

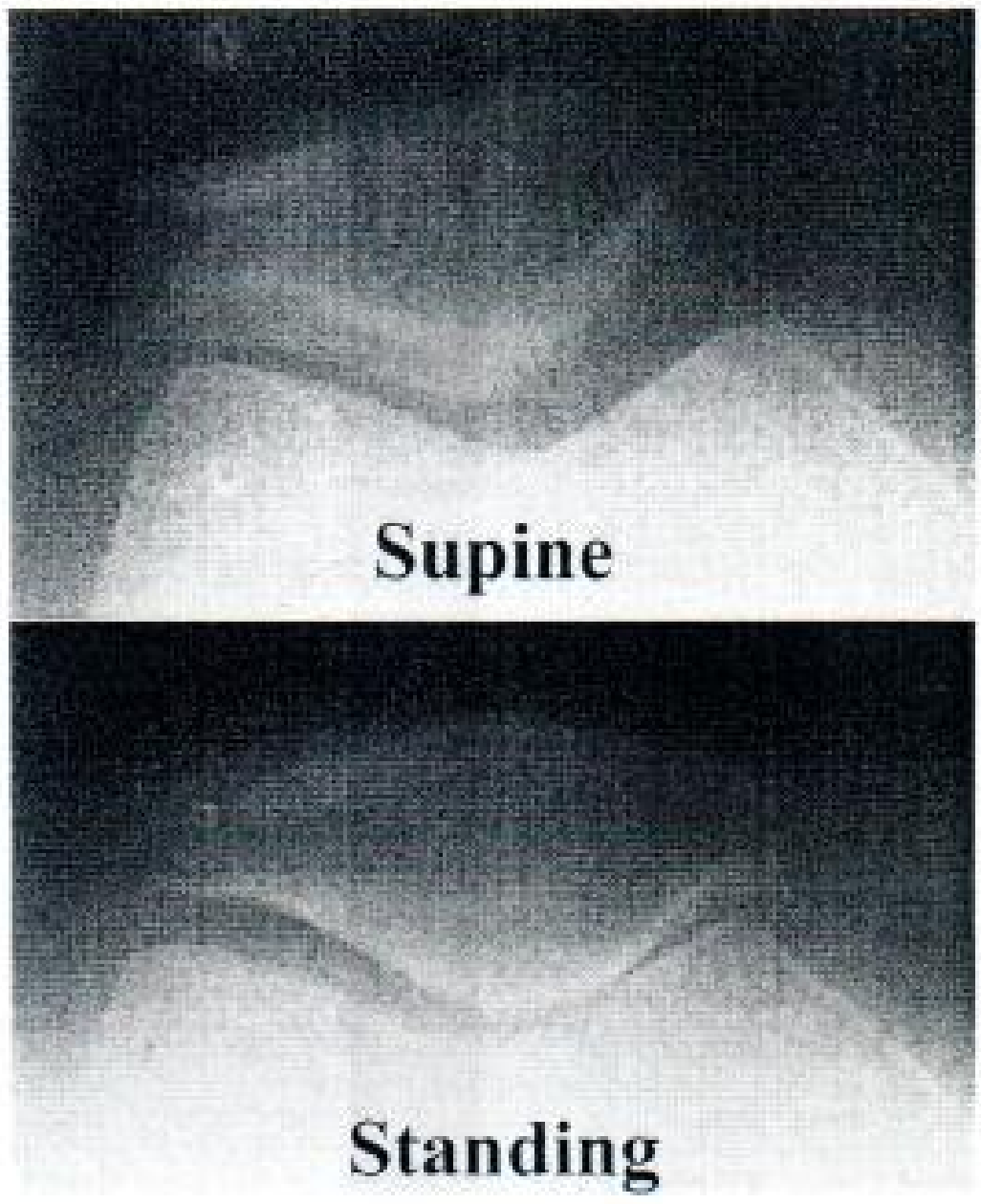

Fig. 13.37. Axial radiographic views obtained in the supine and standing positions in a female with medial femorotibial arthrosis. Stage 2.0 arthrosis in the medial joint space was visualized in the standing position only

In addition to anterior knee pain, many of these patients present with swelling of the knee and effusion with synovitis on contrast-enhanced MR imaging (Figs. 13.33, 13.34). Our imaging protocol in these patients comprises:

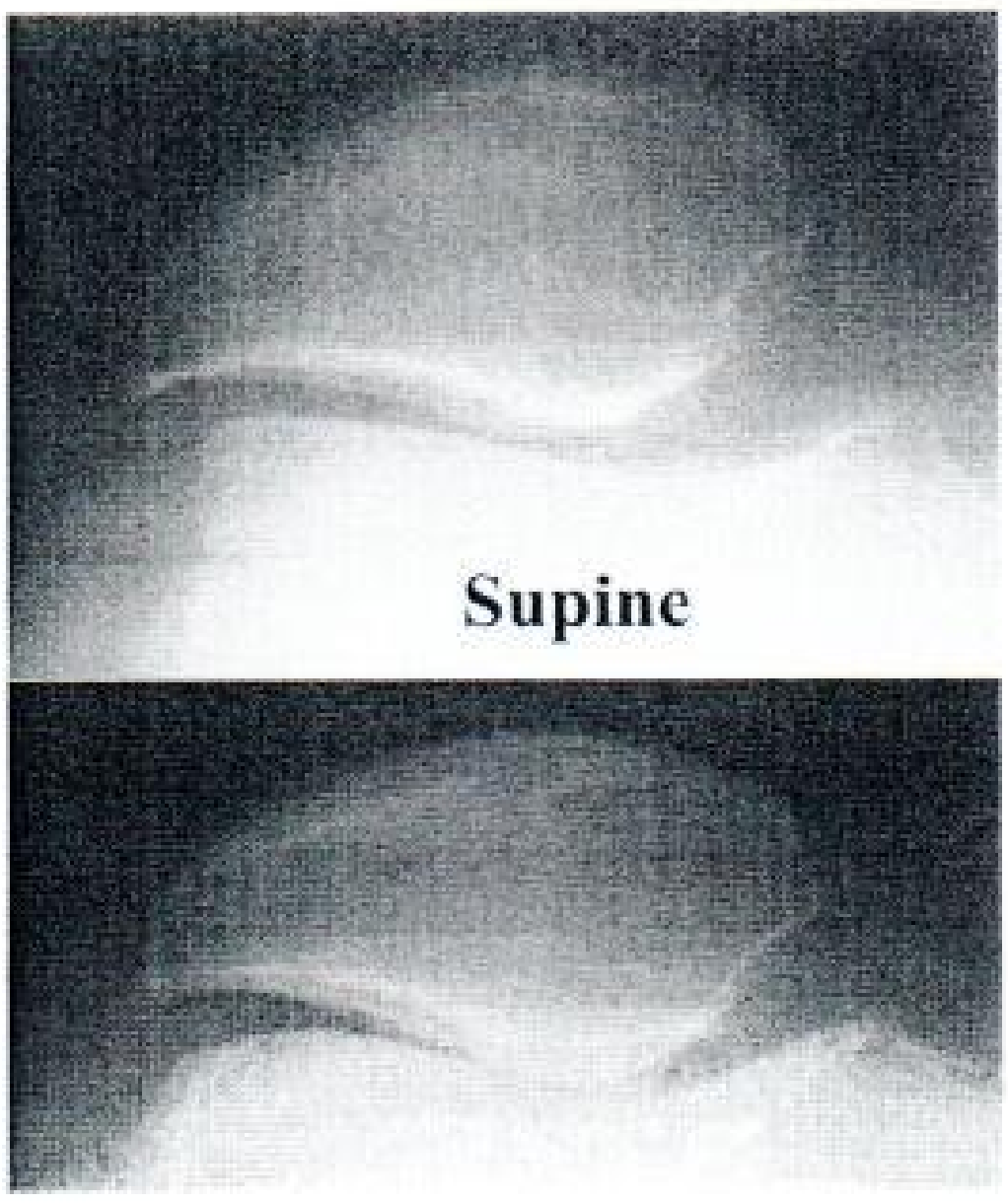

Fig. 13.38. Axial radiographic views of lateral patellar arthrosis visualized in both the supine and the standing position. There is medial displacement of the patella between supine and weight-bearing

1. Sagittal STIR, 512 matrix
2. Sagittal T1, 512 matrix
3. Oblique axial T1, 512 matrix
4. Oblique or double oblique axial proton fat saturated, 512 matrix
5. Sagittal contrast-enhanced T1 fat saturated
6. Oblique or double oblique axial contrast-enhanced T1 fat saturated

The STIR and T1-weighted sequences provide an excellent overview and tissue characterization of soft tissue, bony and cartilaginous abnormalities (Fig. 13.33a). In addition, T1-weighted sequences are sensitive in detecting subchondral abnormalities, which commonly are associated with focal cartilage degeneration but may also precede cartilage deterioration, as suggested by Radin and Rose (1986). Conventional T2-weighted sequences will not visualize these subchondral lesions or bone marrow edema and have little relevance in MR imaging of OA or arthritis. Among the sequences used for cartilage imaging for routine use, we prefer a high-resolution, proton fat-saturated sequence, which allows grading of cartilage degeneration according to Outerbridge (1961) (Figs. 13.34, 13.39, 13.40). When cartilage lesions down to bone are evident on STIR and T1-weighted images, the proton fat-saturated sequence is excluded. Postcontrast T1-weighted sequences with fat saturation allow an overall estimation and grading of the inflammatory component of OA in the synovium and its surrounding soft tissue (Ostergaard et al. 1998) as well as in the subchondral bone and adjacent bone marrow (Fig. 13.33b). Cartilage defects and the common meniscus lesions in femorotibial OA are also well visualized with this postcontrast sequence.

It has been suggested that the role of processes in the subchondral bone relative to those in the adjacent cartilage can be further elucidated by the use of contrast-enhanced measurements of perfusion and permeability (Kuhl and Schild 2000) followed by measurements of changes in the cartilage glycosaminoglycan concentration (Bashir et al. 1999; Burstein et al. 2001).

13.9
Traumatic and Overuse Conditions

Extensor mechanism injuries can occur at all ages but they are most commonly seen in younger patients and in association with sports activities. A distinction must be drawn between acute and chronic injury. For an understanding of the trauma mechanism and what to look for, any traumatic condition is better considered a primary soft tissue injury which may involve bone. In chronic injury and overuse syndromes, it is less appropriate to make a distinction between soft tissue and bone injury, considering the anatomy and the most common sites of injury at tendon attachments to bone and cartilage (Fig. 13.34).

13.9.1
Patellar Dislocation

Patellar dislocation indicates that the patella has been completely displaced from the femoral trochlea. The direction of displacement is almost invariably to the lateral side. *Congenital patellar dislocation* (Fig. 13.41) is commonly associated with neuromuscular deficiencies and frequently requires surgical treatment. Standing radiographs may be helpful in the planning of this treatment (Fig. 13.42). Primary *acute dislocation* may result from direct trauma to the patella, but is most commonly due to a twisting injury on a fixed foot with excessive outward rotation of the tibia at slight to moderate flexion of the knee. A number of predisposing anatomical bone and soft tissue abnormalities have been discussed, the most consistent of these

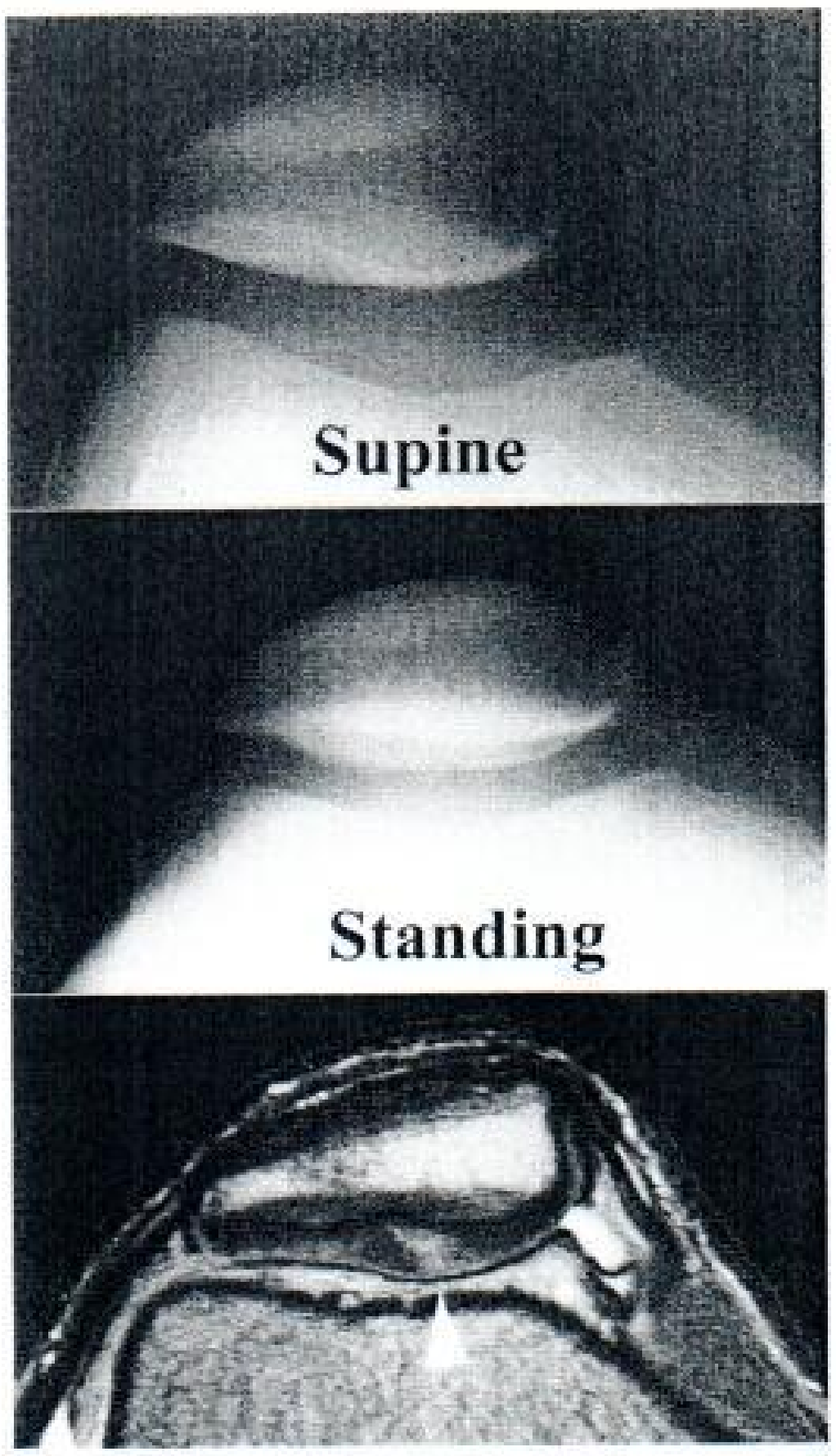

Fig. 13.39. Axial radiographic views of the patellofemoral joint in a 19-year-old male with anterior knee pain and patellar instability, obtained in the supine and standing positions. Proton fat-saturated MR imaging demonstrated localized cartilage edema (*arrowhead*). The patient was a candidate for lateral release until the standing radiographic view demonstrated a normal position of the patella. Notice edema in the bone marrow of the patella. The patient was free of pain after surgical fenestration

being an abnormally high trochlear angle (Brattström 1964), patella alta (Insall et al. 1976), lateral patellar tilt and displacement (Atkin et al. 2000), and generalized ligamentous laxity (Rünow 1983). Around 50% of primary acute dislocations occur in knees without these abnormalities and the result of trauma is most severe in these patients. Arthroscopy may reveal osteochondral lesions involving the patella and the lateral femoral condyle in about two-thirds of patients, many with loose fragments, and tears of the medial patellofemoral ligament are found in almost all knees at open surgical exploration (Sallay et al. 1996; Stanitski 1995; Stanitski and Paletta 1998).

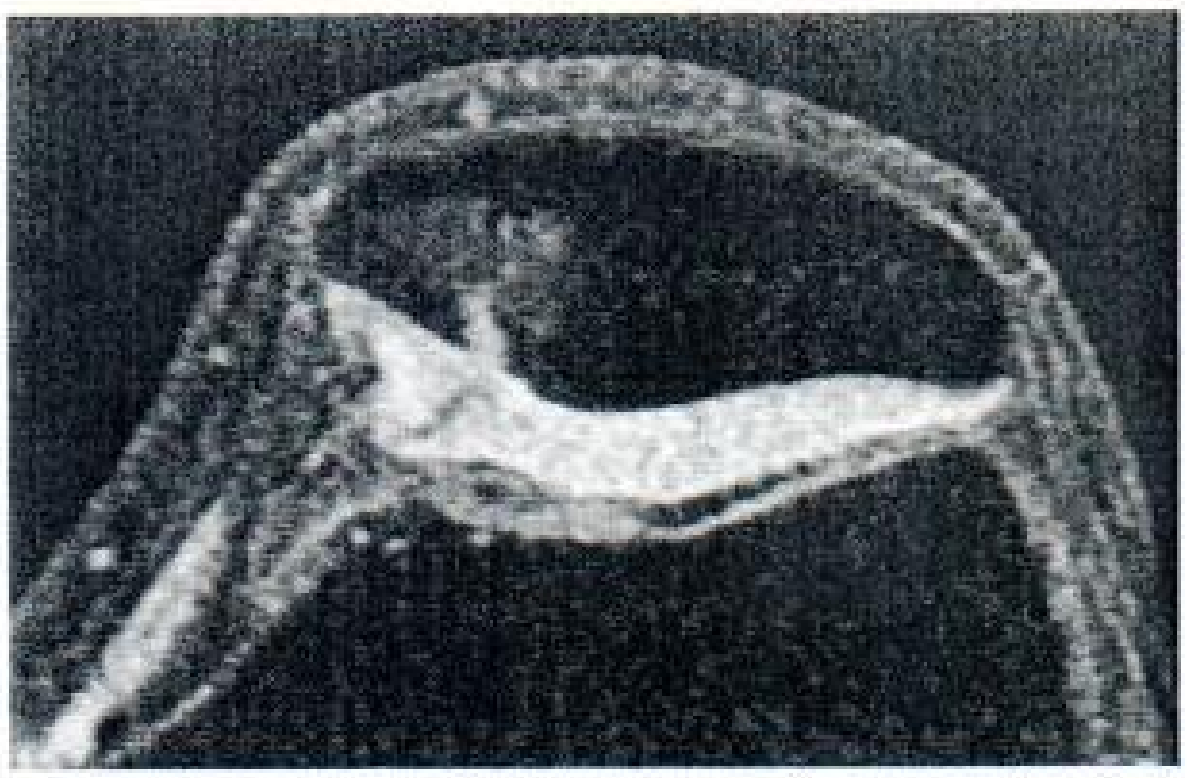

Fig. 13.40. MR image of cartilage fissure and adjacent bone marrow lesions on a 3D SPGR/FLASH sequence. (Courtesy of J. Gelineck, MD, Aarhus, Denmark)

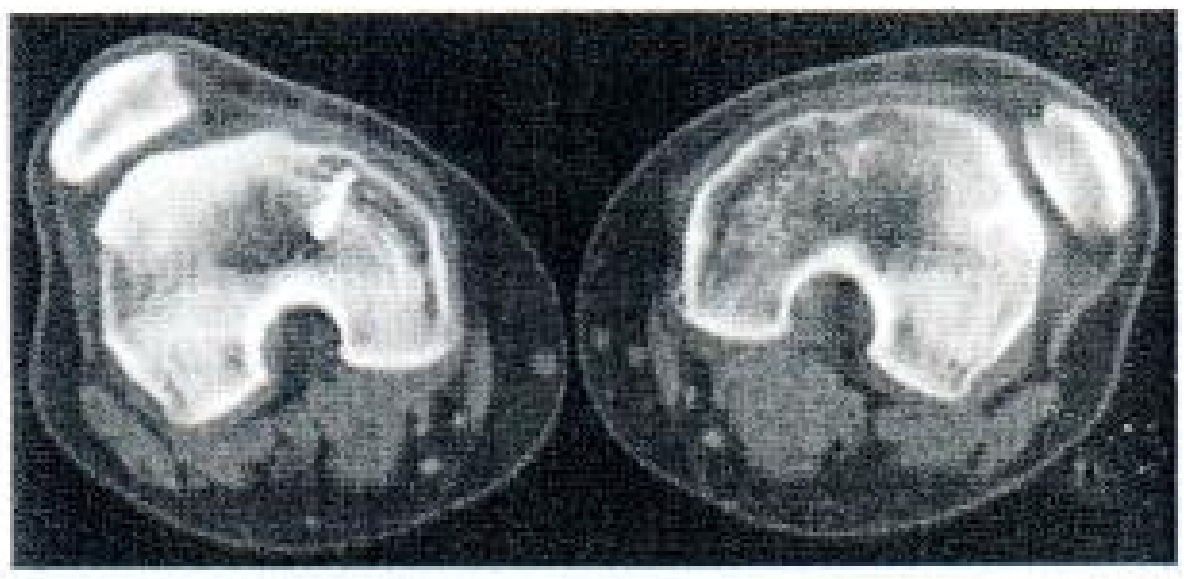

Fig. 13.41. Transaxial CT of the patellofemoral joint in 16-year-old male with congenital patellar displacement who had previously undergone surgery on the right knee. In addition to the large outward rotation of both knees, the patient had abnormal anteversion angles of the hips

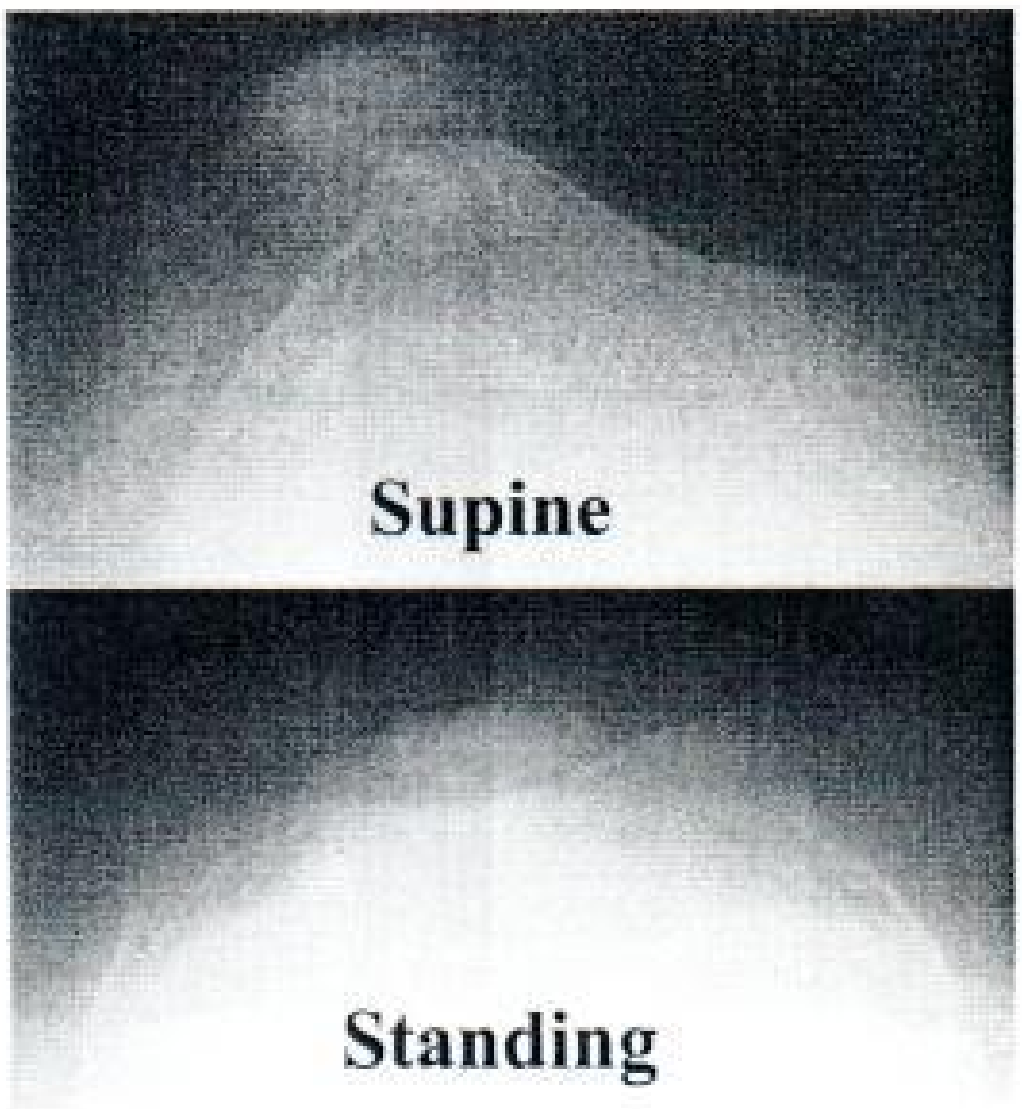

Fig. 13.42. Attempts to obtain axial radiographic views in a patient with congenital patellar displacement in the supine position. There is no patellar displacement in the standing position, which led to an alteration in the planned surgical treatment

13.9.1.1
Imaging of the Knee with Acute Patellar Dislocation

The radiographic examination of acute patellar displacement should include AP, lateral and two oblique views of the knee as well as an axial view of the patellofemoral joint. Almost invariably the radiographic study will demonstrate a large effusion of the suprapatellar bursa and commonly lipohemarthrosis, but few intra-articular loose osteochondral fragments (Fig. 13.43) can be identified (Stanitsky and Paletta 1998). The axial view may demonstrate an avulsion from the medial aspect of the patella (Fig. 13.43) and an increased patellofemoral joint space with lateral patellar displacement due to the effusion.
Figs. 44-49

MR imaging may detect only half of the osteochondral lesions seen at arthroscopy, but most of the lesions of the medial patellofemoral ligament (Sallay et al. 1996). We examine these injuries using a dedicated knee coil at 20° of knee flexion and our standard protocol includes sagittal and axial T1-weighted and STIR sequences (Fig. 13.44), and axial

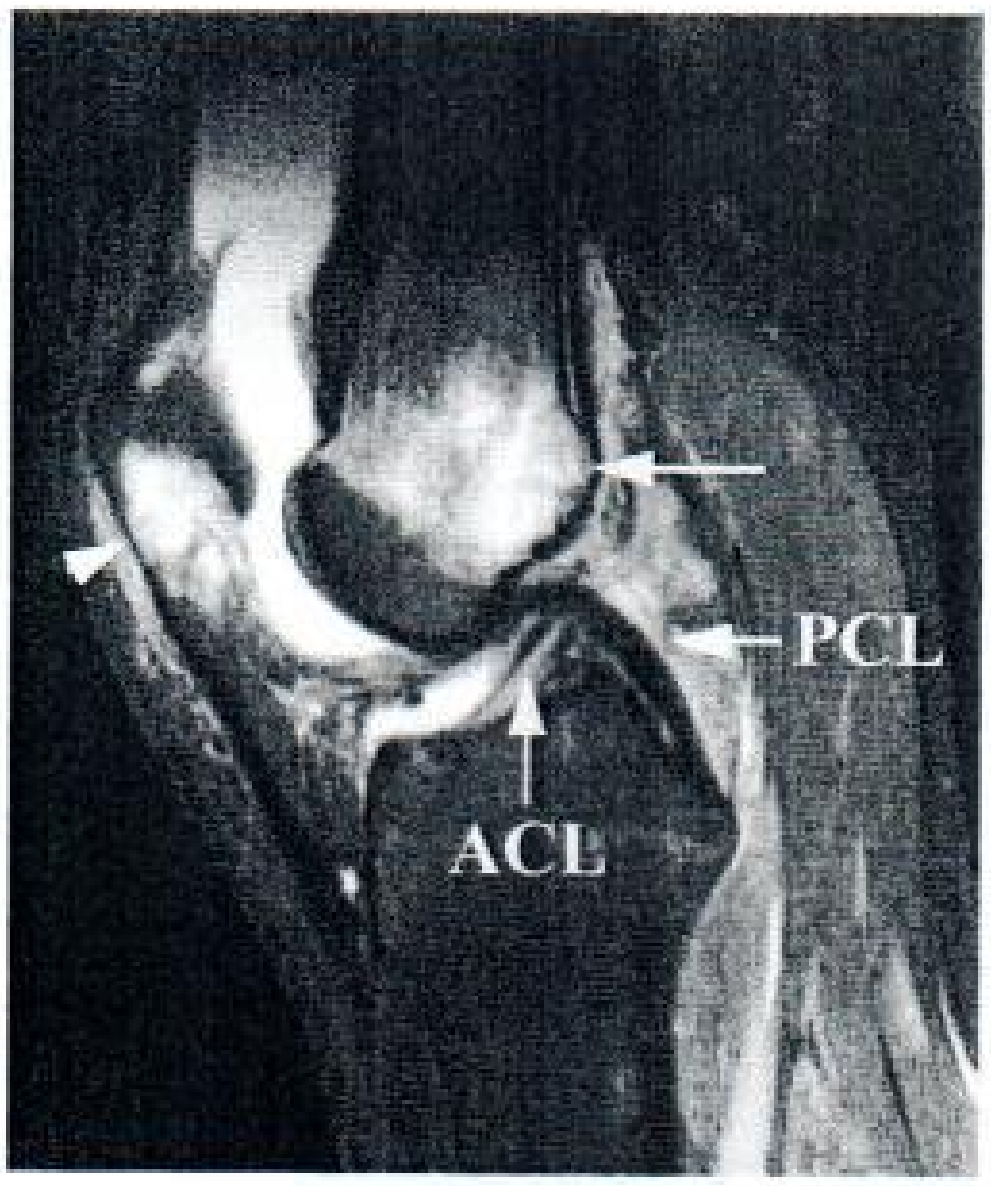

Fig. 13.44. Acute primary patellar dislocation. Sagittal STIR MR sequence sectioning the center of the knee. Joint effusion. There is a bone marrow lesion of the distal half of the patella (*white arrowhead*) and a large bone marrow lesion of the femur (*white arrow*) at the insertion of the anterior (*ACL*) and posterior (*PCL*) cruciate ligaments

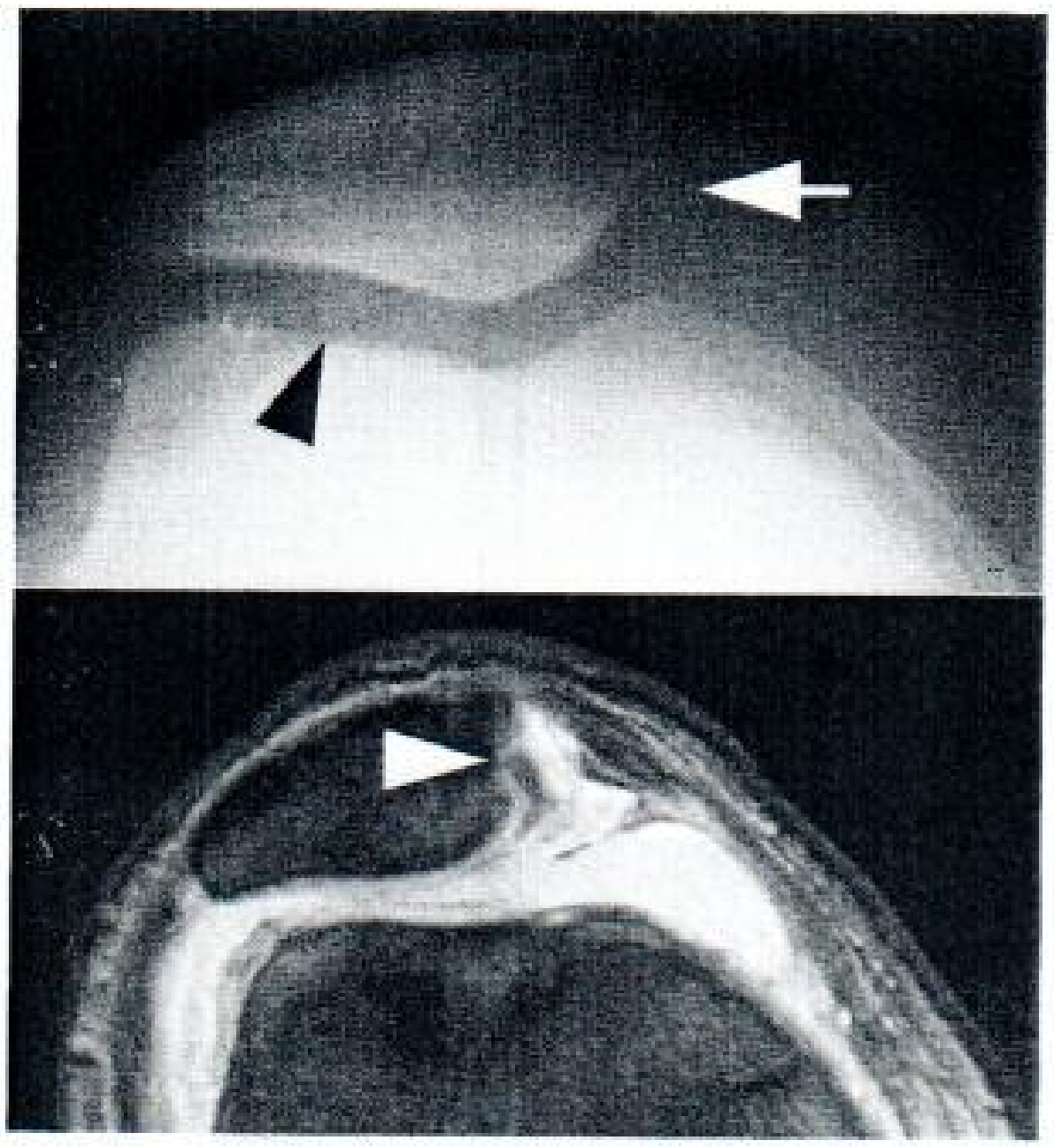

Fig. 13.43. Acute primary patellar dislocation. The axial radiographic view in the standing position (*above*) demonstrates avulsion of an osteochondral fragment from the odd facet of the patella (*white arrow*) and in addition a fragment in the lateral joint space (*black arrowhead*). MR imaging (*below*) confirmed the osteochondral avulsion of the odd facet. For normal anatomy, compare with Fig. 13.6

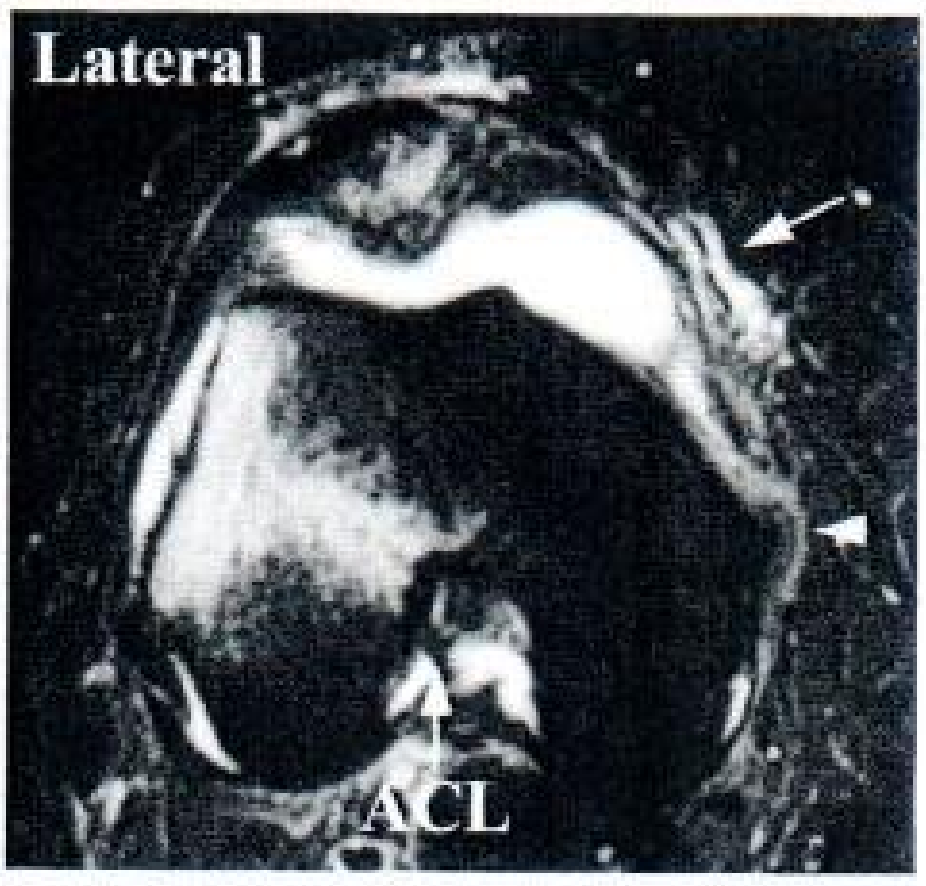

Fig. 13.45. Acute primary patellar dislocation. Transaxial MR section through the femoral condyles with STIR sequence. Joint effusion is present and there are lesions of the middle portion of the medial patellofemoral ligament (*white arrow*) and at the site of the medial collateral ligament (*white arrowhead*). There is a characteristic bone marrow lesion following the contour of the lateral femoral condyle and also a commonly seen bone marrow lesion extending in the lateral direction from the insertion of the anterior cruciate ligament (*ACL*)

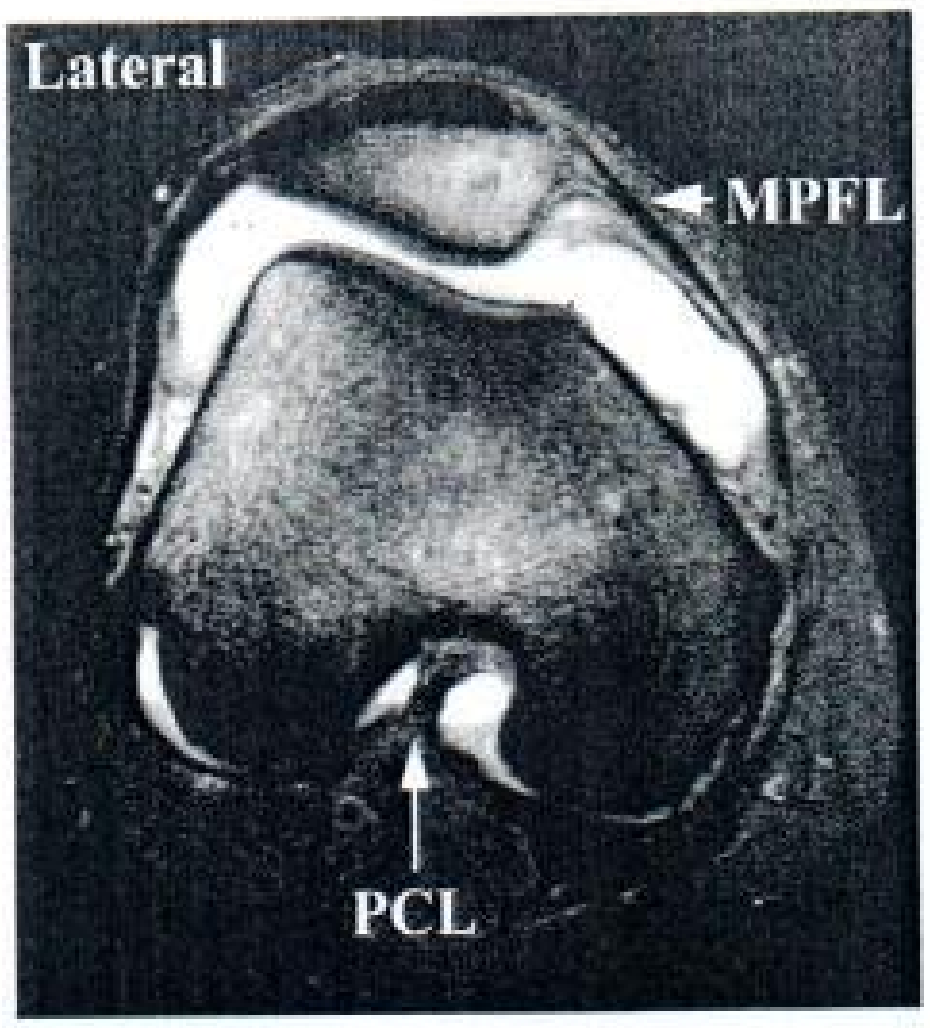

Fig. 13.46. Acute primary patellar dislocation. Transaxial MR section through the femoral condyles on a STIR sequence with a matrix of 512. Joint effusion. There are minor lesions of the medial patellofemoral ligament (*MPFL*) at the insertion on the patella, but at surgery there was also rupture at the attachment on the medial femoral condyle. There is a characteristic bone marrow lesion of the medial two-thirds of the patella and the lateral femoral condyle. In addition, a bone marrow lesion extends from the insertion of the posterior cruciate ligament (*PCL*)

Fig. 13.47. Acute primary patellar dislocation with the characteristic bone marrow lesion of the lateral femoral condyle, and also a lesion of the medial femoral condyle, on a coronal MR STIR sequence

proton with fat saturation, all at a matrix of 512. To date, in 41 acute primary patellar dislocations, we have observed osteochondral lesions in about 40% of cases at arthroscopy, but less than half of these have been visualized at MR imaging (Egund, Wulf, Kristiansen, personal communication) (Figs. 13.43, 13.48, 13.49). Partial and complete tears of the patellofemoral ligament have been seen in all but two cases, and confirmed at surgical repair (Fig. 13.45). Lesions of the medial collateral ligament are common, as are bone marrow lesions. The sites of the latter are characteristic for patellar dislocation (Figs. 13.44–13.47) and indicate a serious rotational injury of the femorotibial joint (Figs. 13.45, 13.46), leaving this with potential ligamentous instability. Complete tears of the anterior or posterior cruciate ligament have not been observed, but the common and characteristic bone marrow lesions adjacent to the ligament insertions in the femoral condyles (Figs. 13.44–13.46, 13.49) may be the result of traction injuries (Egund et al., personal communication in preparation for publication). Acute patellar dislocation may also involve the fat pad of Hoffa (Fig. 13.44) (Apostolaki et al. 1999). Meniscus lesions are seen only occasionally.



Fig. 13.48. Acute primary patellar dislocation with a sagittal MR STIR sequence. The typical bone marrow lesion is demonstrated in the lateral femoral condyle. To visualize most of the osteochondral lesions on MR imaging, transaxial as well as oblique coronal sectioning (shown) is necessary

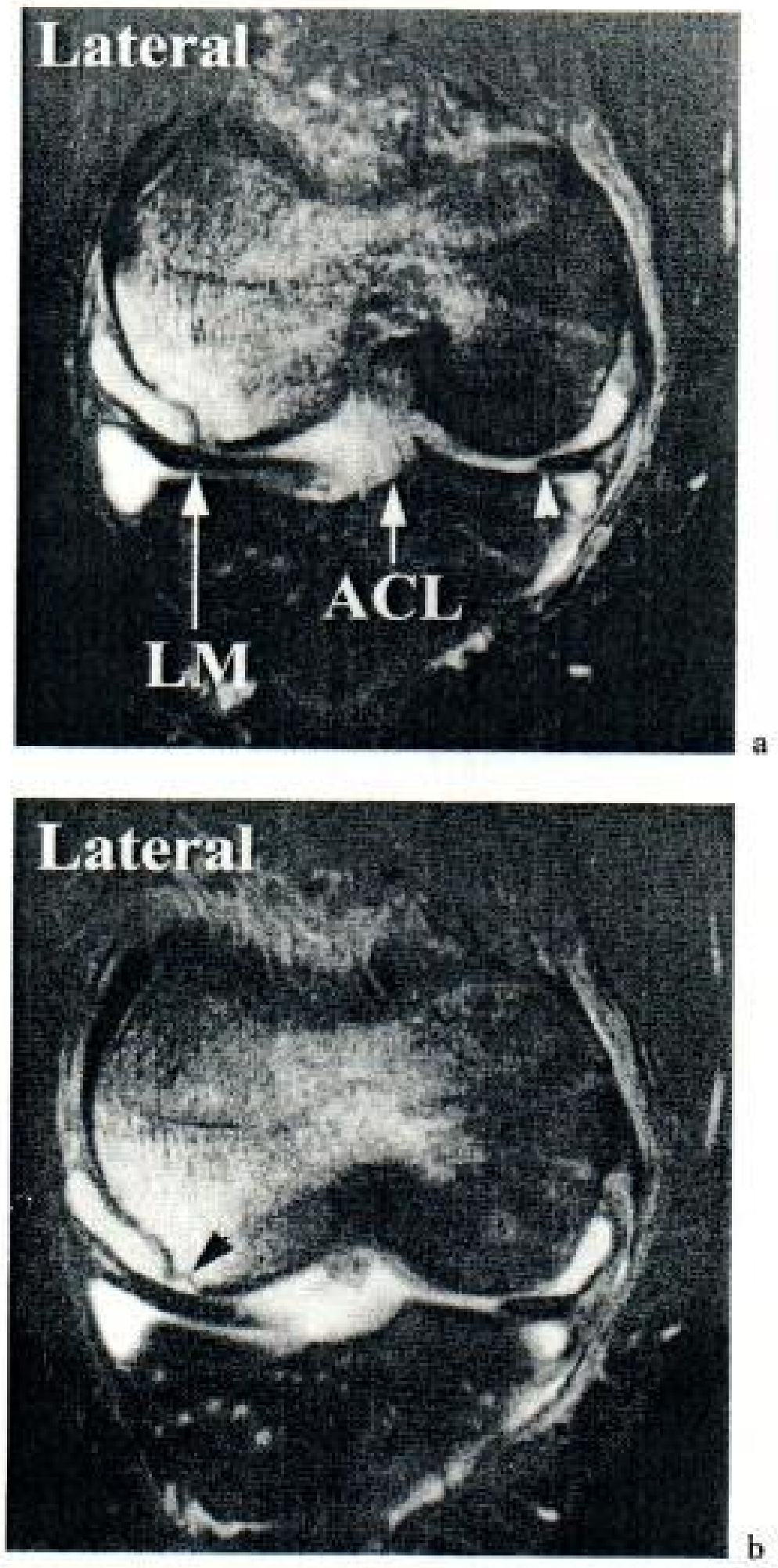

Fig. 13.49a, b. Acute patellar dislocation in the same patient and with the same direction of sectioning as in Fig. 13.48. a The joint effusion contributes to visualization of the anatomy of the anterior portion of the medial (*arrowhead*) and the lateral (*LM*) meniscus and their attachment to the patellar retinaculum. The direction of sectioning may optimize assessment of the anterior cruciate ligament (*ACL*). b Anteriorly there is an osteochondral defect (*black arrowhead*) of the lateral femoral condyle. Large bone marrow lesions are present both laterally and centrally

13.9.2
Recurrent Dislocation of the Patella

Following primary acute dislocation of the patella, most patients have to reduce their sports activities (ATKIN et al. 2000) and will reappear with patellar pain and instability (HAWKINS et al. 1986) or one or more redislocations. Recurrent patellar dislocation has a peak incidence at 14–15 years (range 10–30 years) and occurs more frequently in females (FULKERSON 1997). The surgical treatment of recurrent patellar dislocation remains a challenge to orthopedic surgeons and can be divided into four main types of procedure, combinations of which may be employed:

1. Soft tissue realignment procedures, e.g., lateral release
2. Medial transfer of the tibial tuberosity/internal rotational osteotomy
3. Distal transfer of the tibial tuberosity
4. Osteotomy of the lateral femoral condyle (no long-term results)

The short-term results of these procedures are "good" with regard to redislocation, but less promising in the long term owing to disability, reduced physical activities and development of patellofemoral osteoarthrosis (HAMPSON and HILL 1975; MACNAB 2001; MAENPAA and LEHTO 1997a,b). In comparison with surgery, and independent of the surgical procedure used, conservative treatment may yield better clinical results and reduce the occurrence of osteoarthritis (ARNBJORNSSON et al. 1992). Using weight-bearing radiographic techniques, medial patellofemoral osteoarthritis was recorded in 65% of 114 operated knees, followed up for 14 years, whereas lateral patellofemoral osteoarthritis occurred in only three (ARNBJÖRNSSON et al. 2002). Development of mainly medial femorotibial osteoarthritis may also be related to patellar dislocation (JULIUSSON and MARKHEDE 1984): based on the use of weight-bearing radiographs, its prevalence 14 years following surgery was found to be 52%, with a significant correlation to medial or lateral (3/114) displacement of the patella in the standing position (ARNBJÖRNSSON et al. 2002). In patients with unilateral recurrent patellar dislocation, medial displacement of the patella of the "healthy" knee has been demonstrated in the standing position; in addition, a correlation has been observed between such recurrent dislocation and medial patellofemoral and femorotibial osteoarthrosis (ARNBJÖRNSSON et al. 2001b), comparable to findings in those with conservative treatment of dislocation (ARNBJÖRNSSON et al. 2001a). These observations may be in accordance with those of SANFRIDSSON et al. (2001a), who demonstrated increased inward rotation of the tibia in patients with patellar dislocations.

13.9.2.1
Imaging of the Knee with Recurrent Patellar Dislocation

It is felt that for the routine pre- and postoperative radiological assessment of recurrent patellar dislocation, there is no alternative to the standing weight-bearing radiographic techniques. These should include AP, lateral femorotibial and axial patellofemoral views in 30° of knee flexion (Figs. 13.10, 13.16). Even if there is lateral patellar displacement in the supine position, a normal position or medial displacement of the patella relative to the femoral trochlea on the axial radiographic view in the standing position (Fig. 13.50) may serve as a contraindication to surgical transfer of the tibial tuberosity and lateral release (Fig. 13.39). Use of the Insall-Salvarti index of patellar height has also resulted in many distal transfers of the tibial tuberosity, which can be prevented by the measure suggested by Blackburne and Peel (1977).

Fig. 13.50. Axial radiographic view of the patellofemoral joint obtained in the standing position in a 19-year-old female with anterior knee pain and patellar instability. There is slight medial displacement of the patella. Would any surgeon perform lateral release or medial transfer of the tibial tuberosity following this imaging appearance?

Advanced radiographic (Figs. 13.20, 13.21) and MR imaging (Fig. 13.31) in the standing position with measurements of patellar tracking and femorotibial rotation is still at an early stage of research, but in the next few years may contribute to better understanding and treatment of recurrent dislocation.

13.9.3
Overuse Syndromes

The term „jumper's knee" has been used to describe a common painful condition in athletes of the quadriceps mechanism of the bone-ligament junction at the lower patellar pole and less commonly at the upper patellar pole and tibial tuberosity. The condition is related to sudden and repetitive extension of the knee such as occurs when running, jumping and kicking. The correlation between histopathology, ultrasonography and MR imaging has been well described (Khan et al. 1996, 1997) and indicates that the commonly used term „tendinitis" may be inappropriate and should be replaced by „tendinosis." Histopathology may demonstrate fiber failure, mucoid degeneration, and fibrinoid necrosis. Complete quadriceps or patellar ligament rupture is rare (Sonin et al. 1995). In the skeletally immature athlete a focal fragmentation or acute avulsion may occur at the bony insertion sites of the patellar ligament (Sinding-Larsen-Johansson disease) or the tibial tuberosity (Osgood-Schlatter disease) (Figs. 13.51, 13.52, 13.53).

The primary imaging procedure of patients with a clinical history and symptoms of patellar tendinosis should be sonography (Fig. 13.54). Tendon abnormalities at sonography may not, however, be correlated with symptoms (Cook et al. 1997, 2000). Patellar tendinosis is not uncommonly an accidental finding at MR imaging in patients with anterior knee pain and has characteristic appearances (Khan et al. 1996). The STIR, T2 fat-saturated and T1 gadolinium-enhanced fat-saturated sequences may all demonstrate fiber discontinuity and adjacent abnormalities of the fat pad (Fig. 13.55). The magic angle phenomenon may influence the assessment of patellar

Fig. 13.51. Lateral radiographic view of avulsion from the tibial tuberosity (*arrow*) in a 10-year-old girl with anterior knee pain

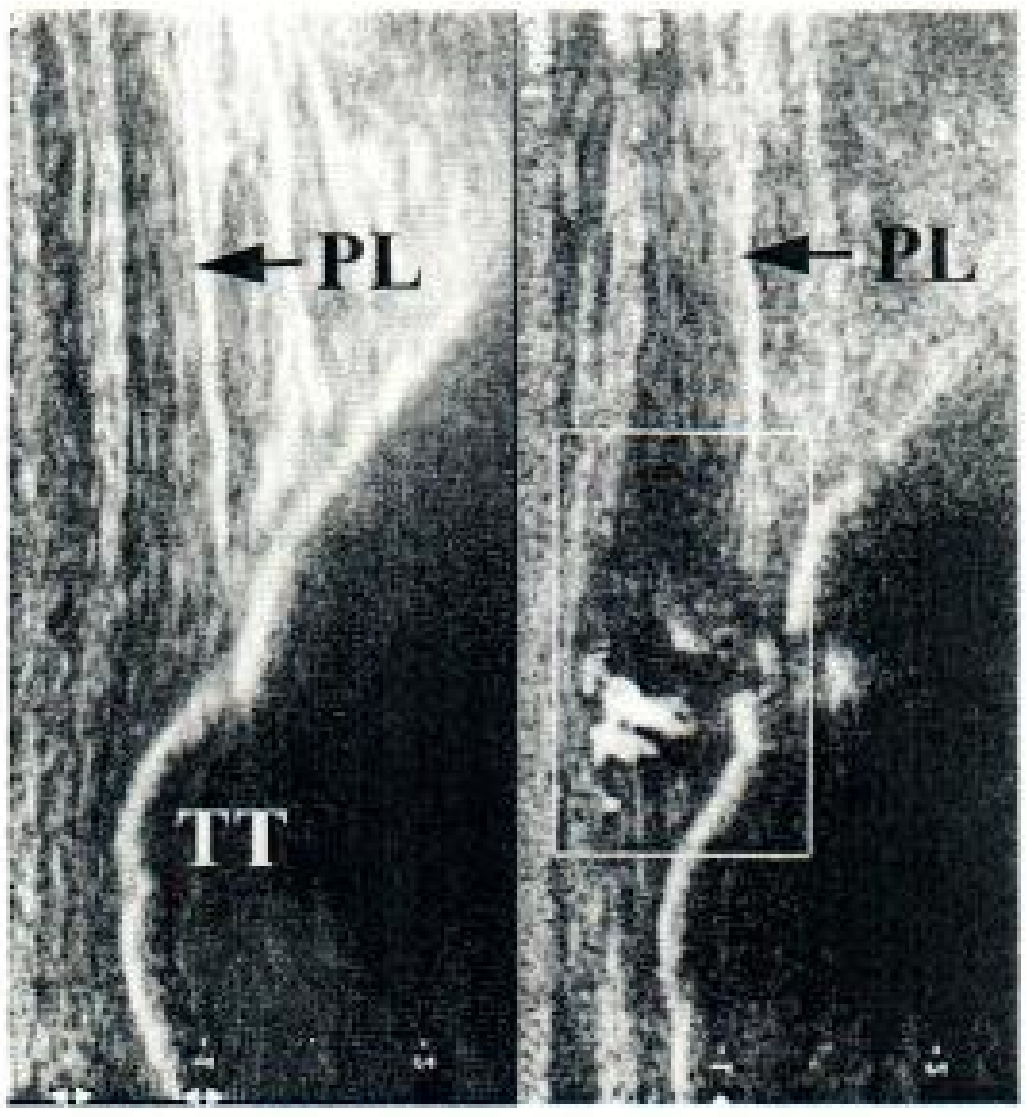

Fig. 13.52. Ultrasonography of the anterior aspect of the tibial tuberosity (*TT*) and patellar ligament (*PL*) in the normal knee (*left*) of the same patient as in Fig. 13.51. The avulsion with its osseous defect is visualized (*right*) with loss of normal structures of the patellar ligament and Doppler enhancement distal to the avulsion

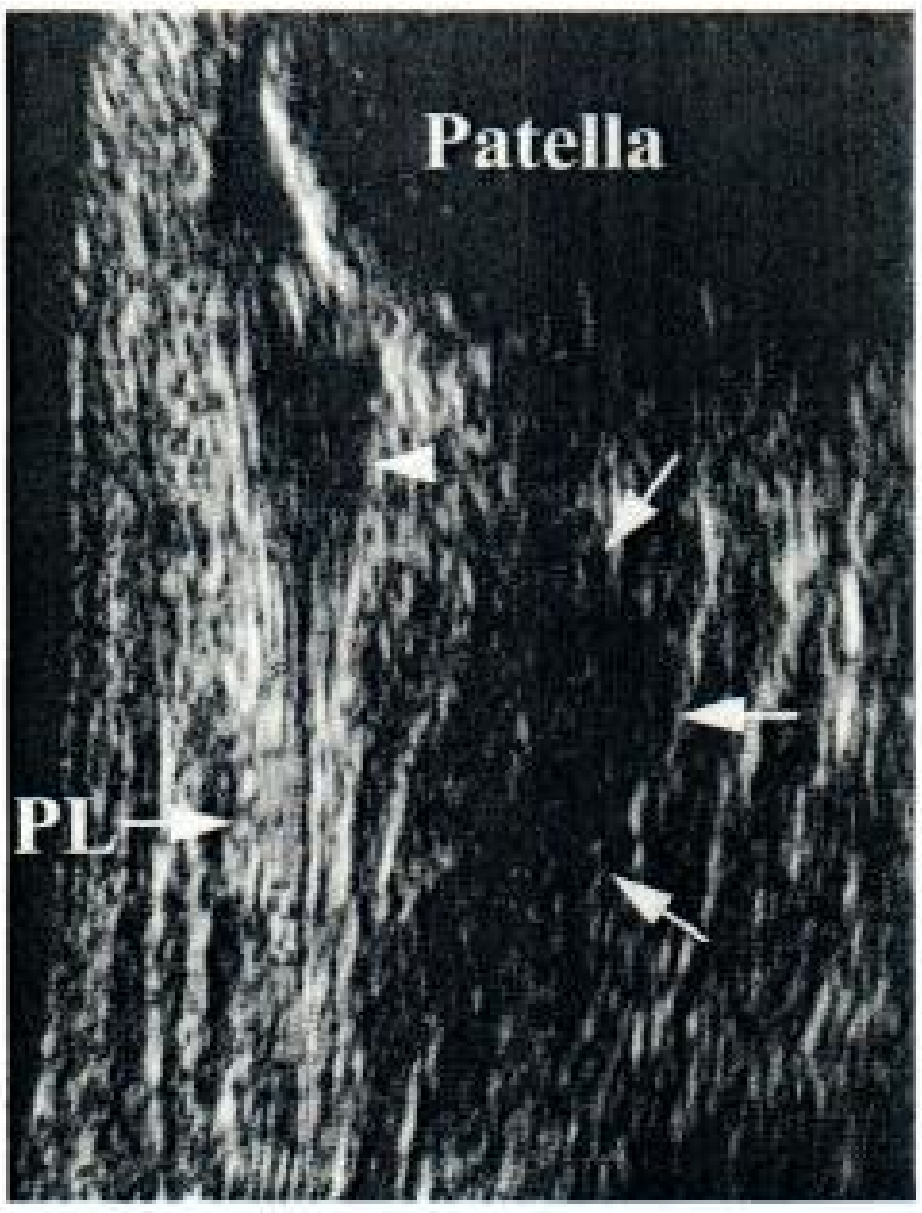

Fig. 13.54. Jumper's knee. Ultrasonography with sagittal direction of sectioning of the anterior aspect of the attachment of the patellar ligament (*PL*) to the patella. There is disruption of fibers of the patellar ligament (*arrowhead*) and inflammatory changes are present in the fat pad of Hoffa (*arrows*). (Courtesy of L. Bolvig, MD, Aarhus, Denmark)

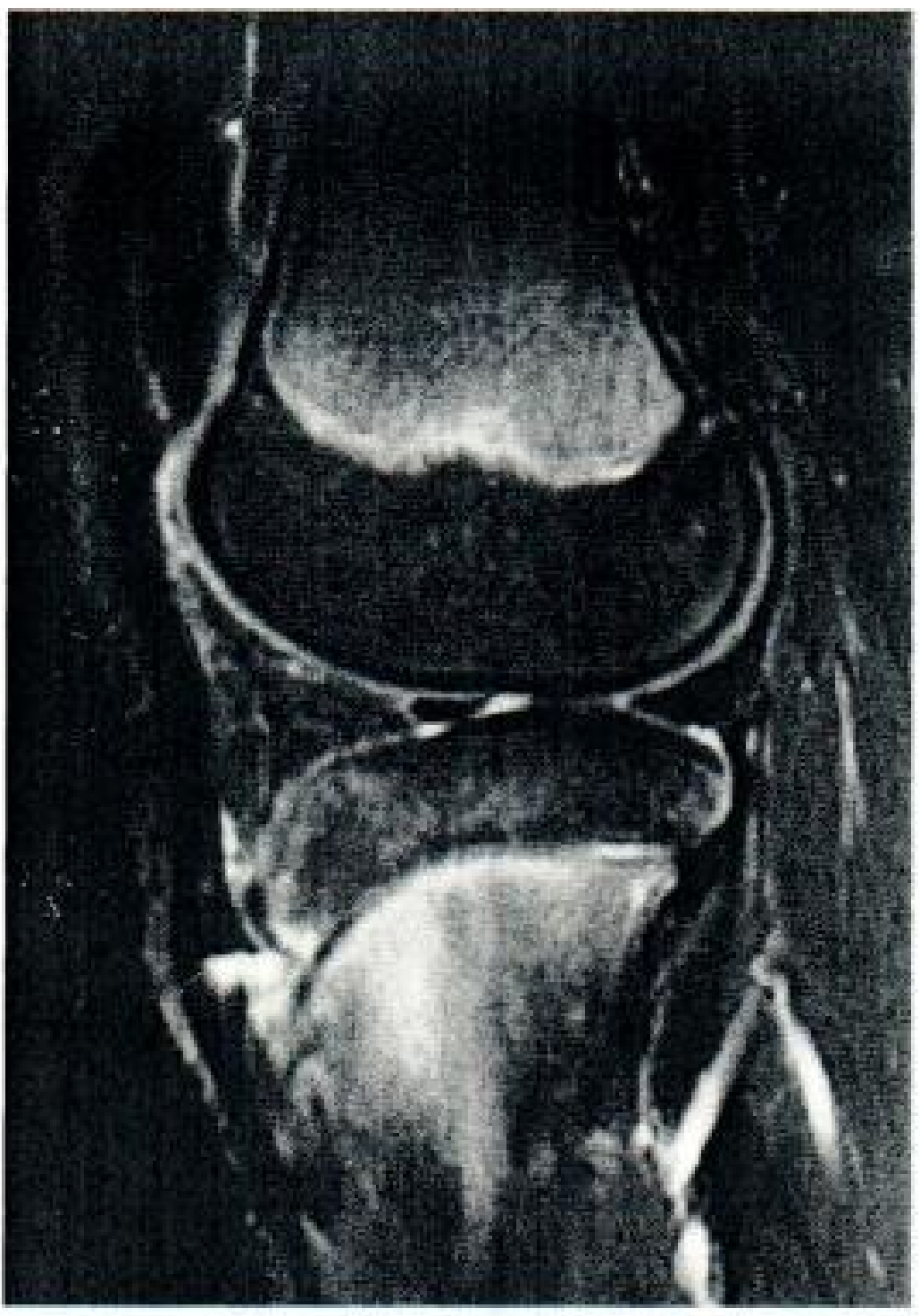

Fig. 13.53. Sagittal MR STIR sequence of the same knee as in Figs. 13.51 and 13.52. The defect of the patellar ligament at the site of the tibial tuberosity is visualized but the sequence does not contribute any additional information compared with Figs. 13.51 and 13.52

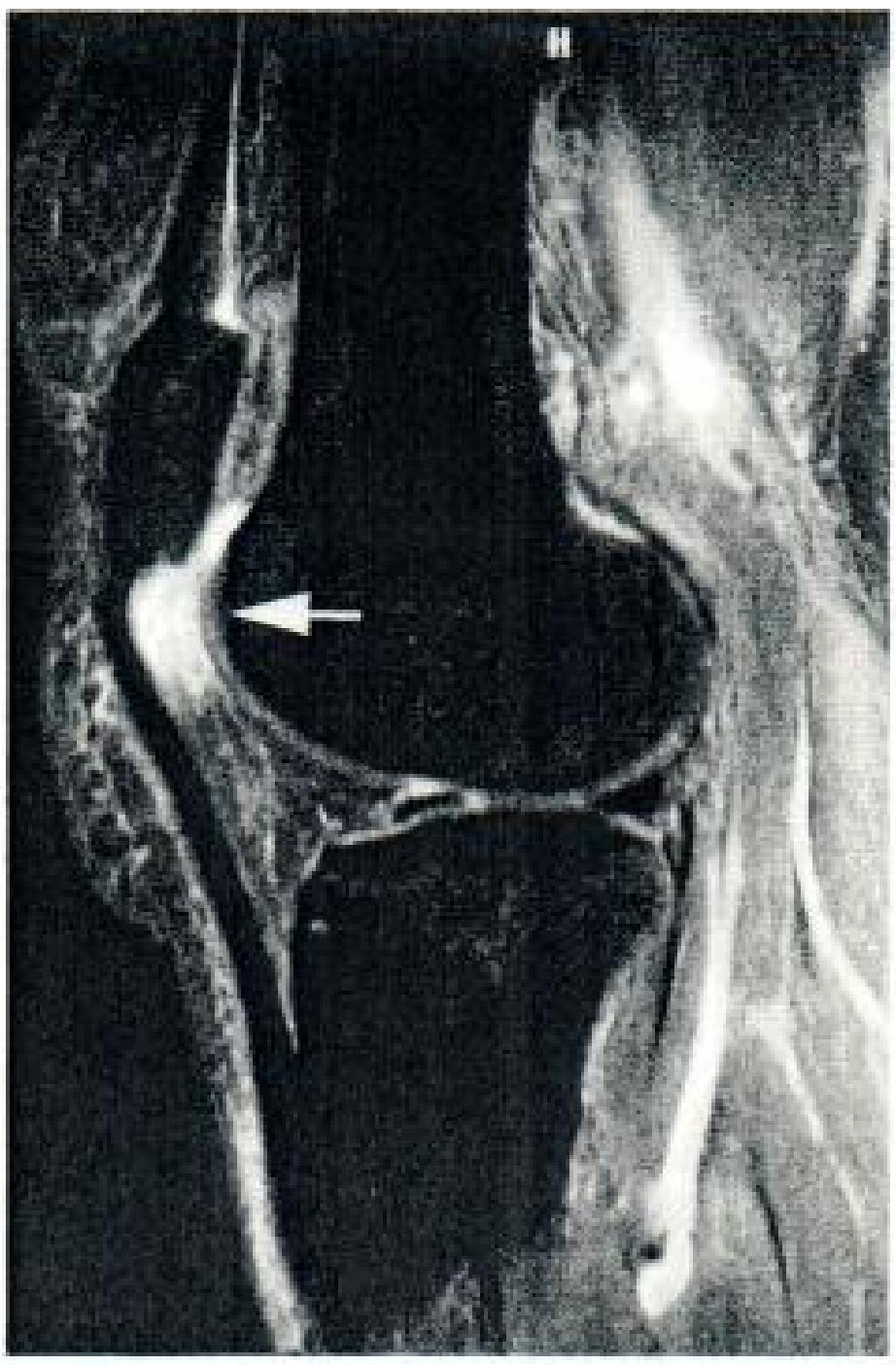

Fig. 13.55. Jumper's knee. Sagittal MR STIR sequence demonstrating a bulging inflammatory lesion of the fat pad of Hoffa (*arrow*) and minor lesions of the patellar ligament at its attachment to the patella

ligament abnormalities (KARANTANAS et al. 2001). Both MR imaging and bone scintigraphy (KAHN and WILSON 1987) may demonstrate bony involvement of the patella.

13.10
Conclusion

For many years the understanding and treatment of patellofemoral disorders has been influenced by conventional radiography and advanced imaging as well as clinical examination obtained in the supine position. We feel that the weight-bearing examination of the patellofemoral joint may contribute not only to more accurate diagnostics but also to the understanding of why anterior knee pain occurs, as requested by INSALL (1995). The weight-bearing techniques of imaging do not immediately open up a new world of treatments for patellofemoral instability, but they may prevent patients from undergoing the traditional surgical treatment, which from a "standing" radiologist's point of view commonly appears contraindicated. Hopefully colleagues worldwide will soon regard the standing examination techniques with the same enthusiasm as has been, and still is, shown for examination in the supine position.

The role of seronegative arthritis and spondylarthropathy with possible involvement of entheses in anterior knee pain has not been explored, but should always be kept in mind when imaging these patients.

References

Ahl T, Dalen N, Selvik G (1988) Mobilization after operation of ankle fractures. Good results of early motion and weight bearing. Acta Orthop Scand 59:302–306

Ahlbäck S (1968) Osteoarthrosis of the knee. A radiographic investigation. Acta Radiol Diagn (Stockh) [Suppl] 72:1–72

Aleman O (1928) Chondromalacia post-traumatica patellae. Acta Chir Scand 63:194

Ando T, Hirose H, Inoue M, Shino K, Doi T (1993) A new method using computed tomographic scan to measure the rectus femoris-patellar tendon Q-angle comparison with conventional method. Clin Orthop 289:213–219

Apostolaki E, Cassar-Pullicino VN, Tyrrell PN, McCall IW (1999) MRI appearances of the infrapatellar fat pad in occult traumatic patellar dislocation. Clin Radiol 54:743–747

Arnbjörnsson A, Egund N, Rydling O, Stockerup R, Ryd L (1992) The natural history of recurrent dislocation of the patella. Long-term results of conservative and operative treatment. J Bone Joint Surg [Br] 74:140–142

Arnbjörnsson A, Egund N, Ryd L (2002) Recurrent dislocation of the patella: the recurrence and site of osteoarthritis in 114 operated knees followed for 14 years. Int Orthop (in press)

Atkin DM, Fithian DC, Marangi KS, Stone ML, Dobson BE, Mendelsohn C (2000) Characteristics of patients with primary acute lateral patellar dislocation and their recovery within the first 6 months of injury. Am J Sports Med 28:472–479

Bashir A, Gray ML, Hartke J, Burstein D (1999) Nondestructive imaging of human cartilage glycosaminoglycan concentration by MRI. Magn Reson Med 41:857–865

Beaconsfield T, Pintore E, Maffulli N, Petri GJ (1994) Radiological measurements in patellofemoral disorders. A review. Clin Orthop 308:18–28

Blackburne JS, Peel TE (1977) A new method of measuring patellar height. J Bone Joint Surg [Br] 59:241–242

Blankevoort L, Huiskes R, de Lange A (1988) The envelope of passive knee joint motion. J Biomech 21:705–720

Boegard T, Rudling O, Petersson IF, Jonsson K (1998a) Correlation between radiographically diagnosed osteophytes and magnetic resonance detected cartilage defects in the patellofemoral joint. Ann Rheum Dis 57:395–400

Boegard T, Rudling O, Petersson IF, Jonsson K (1998b) Joint-space width in the weight-bearing radiogram of the tibiofemoral joint. Should the patient stand on one leg or two? Acta Radiol 39:32–35

Boegard T, Rudling O, Petersson IF, Sanfridsson J, Saxne T, Svensson B, Jonsson K (1998c) Joint-space width in the axial view of the patello-femoral joint. Definitions and comparison with MR imaging. Acta Radiol 39:24–31

Bradley WG, Ominsky SH (1981) Mountain view of the patella. AJR Am J Roentgenol 136:53–58

Brandt KD, Fife RS, Braunstein EM, Katz B (1991) Radiographic grading of the severity of knee osteoarthritis: relation of the Kellgren and Lawrence grade to a grade based on joint space narrowing, and correlation with arthroscopic evidence of articular cartilage degeneration. Arthritis Rheum 34:1381–1386

Brattström H (1964) Shape of the intercondylar groove normally and in recurrent dislocation of patella. A clinical and x-ray-anatomical investigation. Acta Orthop Scand Suppl 68:1–148

Brossmann J, Muhle C, Schroder C, Melchert UH, Bull CC, Spielmann RP, Heller M (1993) Patellar tracking patterns during active and passive knee extension: evaluation with motion-triggered cine MR imaging. Radiology 187:205–212

Brossmann J, Muhle C, Bull CC, Schroder C, Melchert UH, Zieplies J, Spielmann RP, Heller M (1994) Evaluation of patellar tracking in patients with suspected patellar malalignment: cine MR imaging vs arthroscopy. AJR Am J Roentgenol 162:361–367

Buckland-Wright JC (1994) Quantitative radiography of osteoarthritis. Ann Rheum Dis 53:268–275

Burstein D, Velyvis J, Scott KT, Stock KW, Kim YJ, Jaramillo D, Boutin RD, Gray ML (2001) Protocol issues for delayed Gd(DTPA)(2-)-enhanced MRI (dGEMRIC) for clinical evaluation of articular cartilage. Magn Reson Med 45:36–41

Caton J, Deschamps G, Chambat P, Lerat JL, Dejour H (1982) Patella infera. Apropos of 128 cases. Rev Chir Orthop Reparatrice Appar Mot 68:317–325

Cook JL, Khan KM, Harcourt PR, Grant M, Young DA, Bonar SF (1997) A cross sectional study of 100 athletes with jumper's knee managed conservatively and surgically. The Victorian Institute of Sport Tendon Study Group. Br J Sports Med 31:332–336

Cook JL, Khan KM, Kiss ZS, Purdam CR, Griffiths L (2000) Prospective imaging study of asymptomatic patellar tendinopathy in elite junior basketball players. J Ultrasound Med 19:473–479

Delgado-Martins H (1979) A study of the position of the patella using computerised tomography. J Bone Joint Surg [Br] 61:443–444

Dupuy DE, Hangen DH, Zachazewski JE, Boland AL, Palmer W (1997) Kinematic CT of the patellofemoral joint. AJR Am J Roentgenol 169:211–215

Edwards JCV (1998) Synovial physiology in the context of osteoarthritis. In: Brandt KD, Doherty M, Lohmander LS (eds) Osteoarthritis. Oxford University Press, Oxford, pp 167–175

Egund N (1986) The axial view of the patello-femoral joint. Description of a new radiographic method for routine use. Acta Radiol Diagn (Stockh) 27:101–104

Egund N (2001) The radiographic axial view of the patellofemoral joint: examination in the supine or standing position? (abstract). Eur Radiol 11:130

Egund N, Friden T (1988) Lesion of the anterior cruciate ligament and sagittal disalignment of the knee in weight-bearing. Acta Radiol 29:559–563

Egund N, Lundin A, Wallengren NO (1988) The vertical position of the patella. A new radiographic method for routine use. Acta Radiol 29:555–558

Egund N, Friden T, Hjarbaek J, Lindstrand A, Stockerup R (1993) Radiographic assessment of sagittal knee instability in weight bearing. A study on anterior cruciate-deficient knees. Skeletal Radiol 22:177–181

Egund N, Jacobsen BW, Jørgensen A, Kristiansen SE (2000) Angles and shape of the articular surfaces of the tibial condyles: measurement by MR imaging in the sagittal plane. Presented at the European Society of Musculoskeletal Radiology, Leiden

Egund N, Hol PK, Johnston V, Tillung T, Fosse E (2001) Normal femorotibial rotation and patellar tracking in the weight-bearing standing and the non-loaded supine position: assessment and comparison by kinematic MR imaging (abstract). Radiology (Suppl) 609

Felson DT (1998) Epidemiology of osteoarthritis. In: Brandt KD, Doherty M, Lohmander LS (eds) Osteoarthritis. Oxford University Press, Oxford, pp 13–22

Ficat R, Hungerford DS (1977) Disorders of the patello-femoral joint. Williams & Wilkins, Baltimore

Friden T, Sommerlath K, Egund N, Gillquist J, Ryd L, Lindstrand A (1992) Instability after anterior cruciate ligament rupture. Measurements of sagittal laxity compared in 11 cases. Acta Orthop Scand 63:593–598

Friden T, Egund N, Lindstrand A (1993) Comparison of symptomatic versus nonsymptomatic patients with chronic anterior cruciate ligament insufficiency. Radiographic sagittal displacement during weightbearing. Am J Sports Med 21:389–393

Fulkerson JP (1983) The etiology of patellofemoral pain in young, active patients: a prospective study. Clin Orthop 179:129–133

Fulkerson JP (1997) Disorders of the patellofemoral joint. Williams and Wilkins, Baltimore

Fulkerson JP, Shea KP (1990) Disorders of patellofemoral alignment. J Bone Joint Surg [Am] 72:1424–1429

Goodfellow J, Hungerford DS, Woods C (1976) Patello-femoral joint mechanics and pathology. 2. Chondromalacia patellae. J Bone Joint Surg [Br] 58:291–299

Grelsamer RP, Meadows S (1992) The modified Insall-Salvati ratio for assessment of patellar height. Clin Orthop 282:170–176

Hampson WG, Hill P (1975) Late results of transfer of the tibial tubercle for recurrent dislocation of the patella. J Bone Joint Surg [Br] 57:209–213

Harrison MM, Cooke TD, Fisher SB, Griffin MP (1994) Patterns of knee arthrosis and patellar subluxation. Clin Orthop 309:56–63

Hawkins RJ, Bell RH, Anisette G (1986) Acute patellar dislocations. The natural history. Am J Sports Med 14:117–120

Henche HR, Kunzi HU, Morscher E (1981) The areas of contact pressure in the patello-femoral joint. Int Orthop 4:279–281

Hungerford DS, Barry M (1979) Biomechanics of the patellofemoral joint. Clin Orthop 144:9–15

Insall JN (1995) Foreword. In: Scuderi GR (ed) The patella. Springer, Berlin Heidelberg New York

Insall JN, Salvarti E (1971) Patella position in the normal knee. Radiology 101:101–104

Insall JN, Falvo KA, Wise DW (1976) Chondromalacia patellae. A prospective study. J Bone Joint Surg [Am] 58:1–8

Jaroschy W (1924) Die diagnostiche Verwertbarkeit der Patellaraufnahmen. Fortschr Roentgenstr 31:781–782

Jones RB, Barlett EC, Vainright JR, Carroll RG (1995) CT determination of tibial tubercle lateralization in patients presenting with anterior knee pain. Skeletal Radiol 24:505–509

Juliusson R, Markhede G (1984) A modified Hauser procedure for recurrent dislocation of the patella. A long-term follow-up study with special reference to osteoarthritis. Arch Orthop Trauma Surg 103:42–46

Kahn D, Wilson MA (1987) Bone scintigraphic findings in patellar tendonitis. J Nucl Med 28:1768–1770

Karantanas AH, Zibis AH, Papanikolaou N (2001) Increased signal intensity on fat-suppressed three-dimensional T1-weighted pulse sequences in patellar tendon: magic angle effect? Skeletal Radiol 30:67–71

Kärrholm J, Hansson LI, Svensson K (1983) Prediction of growth pattern after ankle fractures in children. J Pediatr Orthop 3:319–325

Kärrholm J, Selvik G, Elmqvist LG, Hansson LI (1988) Active knee motion after cruciate ligament rupture. Stereoradiography. Acta Orthop Scand 59:158–164

Kärrholm J, Borssen B, Lowenhielm G, Snorrason F (1994a) Does early micromotion of femoral stem prostheses matter? 4–7-year stereoradiographic follow-up of 84 cemented prostheses. J Bone Joint Surg [Br] 76:912–917

Kärrholm J, Jonsson H, Nilsson KG, Soderqvist I (1994b) Kinematics of successful knee prostheses during weight-bearing: three-dimensional movements and positions of screw axes in the Tricon-M and Miller-Galante designs. Knee Surg Sports Traumatol Arthrosc 2:50–59

Keats TE (1996) Atlas of normal roentgen variants that may simulate disease. Mosby, St Louis

Kellgren JH, Lawrence JS (1957) Radiologic assessment of osteoarthritis. Ann Rheum Dis 16:494–501

Khan KM, Bonar F, Desmond PM, Cook JL, Young DA, Visentini PJ, Fehrmann MW, Kiss ZS, O'Brien PA, Harcourt PR, Dowling RJ, O'Sullivan RM, Crichton KJ, Tress BM, Wark JD (1996) Patellar tendinosis (jumper's knee): findings at histopathologic examination, US, and MR imaging. Victorian Institute of Sport Tendon Study Group. Radiology 200:821–827

Khan KM, Cook JL, Kiss ZS, Visentini PJ, Fehrmann MW, Harcourt PR, Tress BW, Wark JD (1997) Patellar tendon ultrasonography and jumper's knee in female basketball players: a longitudinal study. Clin J Sport Med 7:199–206

Knutsson F (1941) Über die Röntgenologie des Femoropatellargelenks sowie eine gute Projektion für das Kniegelenk. Acta Radiol Diagn (Stockh) 22:371–376

Kuhl CK, Schild HH (2000) Dynamic image interpretation of MRI of the breast. J Magn Reson Imaging 12:965–974

Langer M (1929) Über die Entwicklung des Kniegelenkes. Z Gesamte Anat 89:83–101

Laurin CA, Levesque HP, Dussault R, Labelle H, Peides JP (1978) The abnormal lateral patellofemoral angle: a diagnostic roentgenographic sign of recurrent patellar subluxation. J Bone Joint Surg [Am] 60:55–60

Laurin CA, Dussault R, Levesque HP (1979) The tangential x-ray investigation of the patellofemoral joint: x-ray technique, diagnostic criteria and their interpretation. Clin Orthop 144:16–26

Ledingham J, Regan M, Jones A, Doherty M (1993) Radiographic patterns and associations of osteoarthritis of the knee in patients referred to hospital. Ann Rheum Dis 52:520–526

Macnab J (2001) Recurrent dislocation of the patella. J Bone Joint Surg [Am] 34:957–967

Mäenpaa H, Lehto MU (1997a) Patellar dislocation. The long-term results of nonoperative management in 100 patients. Am J Sports Med 25:213–217

Mäenpaa H, Lehto MU (1997b) Patellofemoral osteoarthritis after patellar dislocation. Clin Orthop 339:156–162

Martinez S, Korobkin M, Fondren FB, Hedlund LW, Goldner JL (1983a) Computed tomography of the normal patellofemoral joint. Invest Radiol 18:249–253

Martinez S, Korobkin M, Fondren FB, Hedlund LW, Goldner JL (1983b) Diagnosis of patellofemoral malalignment by computed tomography. J Comput Assist Tomogr 7:1050–1053

McNally EG, Ostlere SJ, Pal C, Phillips A, Reid H, Dodd C (2000) Assessment of patellar maltracking using combined static and dynamic MRI. Eur Radiol 10:1051–1055

Merchant AC (1988) Classification of patellofemoral disorders. Arthroscopy 4:235–240

Merchant AC, Mercer RL, Jacobsen RH, Cool CR (1974) Roentgenographic analysis of patellofemoral congruence. J Bone Joint Surg [Am] 56:1391–1396

Moore TM, Harvey JP (1974) Roentgenographic measurement of tibial-plateau depression due to fracture. J Bone Joint Surg [Am] 56:155–160

Muneta T, Yamamoto H, Ishibashi T, Asahina S, Furuya K (1994) Computerized tomographic analysis of tibial tubercle position in the painful female patellofemoral joint. Am J Sports Med 22:67–71

Nagamine R, Miura H, Inoue Y, Tanaka K, Urabe K, Okamoto Y, Nishizawa M, Iwamoto Y (1997) Malposition of the tibial tubercle during flexion in knees with patellofemoral arthritis. Skeletal Radiol 26:597–601

Nagamine R, Miura H, Urabe K, Matsuda S, Chen WJ, Matsunobu T, Iwamoto Y (1999) Radiological assessment of the position of the tibial tuberosity by means of a marking wire in knees with patellofemoral arthritis. Skeletal Radiol 28:27–32

Önsten I, Bengner U, Besjakov J (1993) Socket migration after Charnley arthroplasty in rheumatoid arthritis and osteoarthritis. A roentgen stereophotogrammetric study. J Bone Joint Surg [Br] 75:677–680

Østergaard M, Stoltenberg M, Lovgreen-Nielsen P, Volck B, Sonne-Holm S, Lorenzen I (1998) Quantification of synovitis by MRI: correlation between dynamic and static gadolinium-enhanced magnetic resonance imaging and microscopic and macroscopic signs of synovial inflammation. Magn Reson Imaging 16:743–754

Outerbridge R (1961) The etiology of chondromalacia patellae. J Bone Joint Surg [Br] 43:752–757

Post WR (1997) History and physical examination. In: Fulkerson JP (ed) Disorders of the patellofemoral joint. Williams and Wilkins, Baltimore, pp 39–71

Radin EL (1979) A rational approach to the treatment of patellofemoral pain. Clin Orthop 144:107–109

Radin EL, Rose RM (1986) Role of subchondral bone in the initiation and progression of cartilage damage. Clin Orthop 213:34–40

Ragnarsson JI, Eliasson P, Karrholm J, Lundstrom B (1992) The accuracy of measurements of femoral neck fractures. Conventional radiography versus roentgen stereophotogrammetric analysis. Acta Orthop Scand 63:152–156

Resnick D, Niwayama G (1995) Degenerative diseases. In: Resnick D (ed) Diagnosis of bone and joint disorders. Saunders, Philadelphia, pp 1263–1371

Rünow A (1983) The dislocating patella. Etiology and prognosis in relation to generalized joint laxity and anatomy of the patellar articulation. Acta Orthop Scand Suppl 201:1–53

Ryd L, Lindstrand A, Rosenquist R, Selvik G (1986) Tibial component fixation in knee arthroplasty. Clin Orthop 213:141–149

Ryd L, Albrektsson BE, Carlsson L, Dansgard F, Herberts P, Lindstrand A, Regner L, Toksvig-Larsen S (1995) Roentgen stereophotogrammetric analysis as a predictor of mechanical loosening of knee prostheses. J Bone Joint Surg [Br] 77:377–383

Sallay PI, Poggi J, Speer KP, Garrett WE (1996) Acute dislocation of the patella. A correlative pathoanatomic study. Am J Sports Med 24:52–60

Sanfridsson J, Arnbjornsson A, Friden T, Ryd L, Svahn G, Jonsson K (2001a) Femorotibial rotation and the Q-angle related to the dislocating patella. Acta Radiol 42:218–224

Sanfridsson J, Ryd L, Svahn G, Friden T, Jonsson K (2001b) Radiographic measurement of femorotibial rotation in weight-bearing. The influence of flexion and extension in the knee on the extensor mechanism and angles of the lower extremity in a healthy population. Acta Radiol 42:207–217

Schutzer SF, Ramsby GR, Fulkerson JP (1986) Computed tomographic classification of patellofemoral pain patients. Orthop Clin North Am 17:235–248

Scuderi GR (1995) The patella. Springer, Berlin Heidelberg New York

Seil R, Muller B, Georg T, Kohn D, Rupp S (2000) Reliability and interobserver variability in radiological patellar height ratios. Knee Surg Sports Traumatol Arthrosc 8:231–236

Selvik G (1974) A roentgen stereophotogrammetric method for the study of the kinematics of the skeletal system. Lund University, Sweden

Settegast J (1921) Typische Röntgenbilder von normalen Menschen. Lehmanns Med Atlanten 5:211

Shellock FG, Mink JH, Deutsch AL, Fox JM (1989) Patellar tracking abnormalities: clinical experience with kinematic MR imaging in 130 patients. Radiology 172:799–804

Siu D, Cooke TD, Broekhoven LD, Lam M, Fisher B, Saunders G, Challis TW (1991) A standardized technique for lower limb radiography. Practice, applications, and error analysis. Invest Radiol 26:71–77

Sonin AH, Fitzgerald SW, Bresler ME, Kirsch MD, Hoff FL, Friedman H (1995) MR imaging appearance of the extensor mechanism of the knee: functional anatomy and injury patterns. Radiographics 15:367–382

Spector TD, Hochberg MC (1994) Methodological problems in the epidemiological study of osteoarthritis. Ann Rheum Dis 53:143–146

Stanitski CL (1995) Articular hypermobility and chondral injury in patients with acute patellar dislocation. Am J Sports Med 23:146–150

Stanitski CL, Paletta GA (1998) Articular cartilage injury with acute patellar dislocation in adolescents. Arthroscopic and radiographic correlation. Am J Sports Med 26:52–55

Starok M, Lenchik L, Trudell D, Resnick D (1997) Normal patellar retinaculum: MR and sonographic imaging with cadaveric correlation. AJR Am J Roentgenol 168:1493–1499

Stein LA, Endicott AN, Sampalis JS, Kaplow MA, Patel MD, Mitchell NS (1993) Motion of the patella during walking: a video digital-fluoroscopic study in healthy volunteers. AJR Am J Roentgenol 161:617–620

Thomee R, Augustsson J, Karlsson J (1999) Patellofemoral pain syndrome: a review of current issues. Sports Med 28:245–262

Uvehammer J, Karrholm J, Brandsson S (2000) In vivo kinematics of total knee arthroplasty. Concave versus posterior-stabilised tibial joint surface. J Bone Joint Surg [Br] 82:499–505

van den Berg WB, van der Kraan PM, van Beuningen HM (1998) Synovial mediators of cartilage damage and repair in OA. In: Brandt KD, Doherty M, Lohmander LS (eds) Osteoarthritis. Oxford University Press, Oxford, pp 157–167

Wiberg G (1941) Roentgenographic and anatomic studies on the femoro-patellar joint. Acta Orthop Scand 12:319–410

Woodland LH, Francis RS (1992) Parameters and comparisons of the quadriceps angle of college-aged men and women in the supine and standing positions. Am J Sports Med 20:208–211