A-kursus i kar-radiologi: Ultralyd af arterier

Jonas Eiberg
Karkirugisk afdeling

"BASIC" vascular ultrasound

- Infrarenal aorta
- Screening for aorto-iliac disease by visual interpretation of the flow-curve in the femoral artery
- Supra-genicular arteries
- Peripheral bypass's (stenoses and occlusions)
- Superficial and deep venous insufficiency

"ADVANCED" vascular ultrasound

- Carotid, vertebral and subclavian arteries
- Renal and mesenteric arteries
- Iliac arteries
- Infra-genicular arteries
- Ultrasound contrast
- Ultrasound intervention (Pseudoaneurysms thrombin injection)

- *Only for a few dedicated technologist (MD's)*
- *Only in departments with interest and a dedicated ultrasound section*

Minimum training requirements

Type of ultrasound examination	Number of examinations
Abdominal Aortic Aneurism	10 (Bailey 2001, Kuhn 2000)
US of supragenicular arteries	15(-50) (Eiberg, 2008)
US of infragenicular arteries	100 (Eiberg 2008)
Gallbladder /acute abdomen	20-30 (Eiberg 2008, Jang 2004, Kell 2002, Williams 1994)
Focused Assessment Sonogram in Trauma (FAST)	30(-100) (Gracias 2001, Jang 2004, McCarter 2000)
Echocardiography, adult	20-40 (Akinboboye 1995, Hellmann 2005, Royse 2006)
Fetal anomalies	2000 (Tegnander 2006, Taipale 2003)

Ultrasound of abominal aortic aneurysms (AAA)

- Aneurism or not?
- Size of the aneurism?
- Infra- or suprarenal?
- Extending into the iliac arteries?
- Rupture?

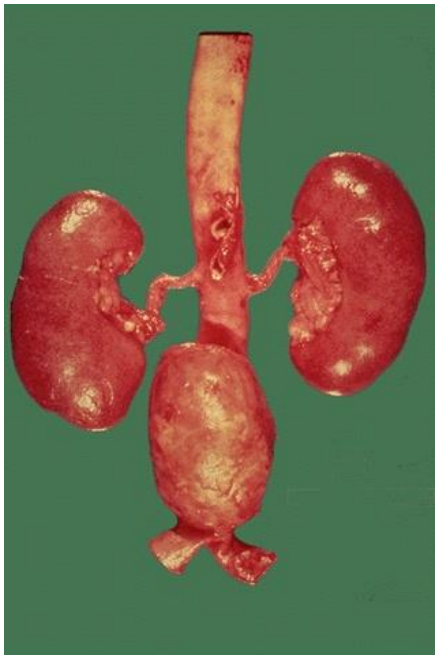

Transverse imaging

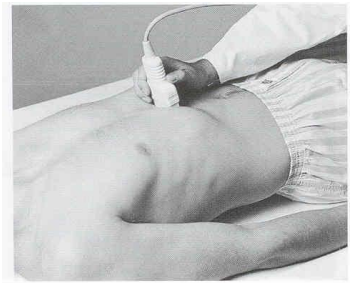

- Measure largest AP (anteroposterior) diameter
- From outer wall to outer wall
- AP is probably more accurate than lateral diameter (vessel wall parallel to the US beam)

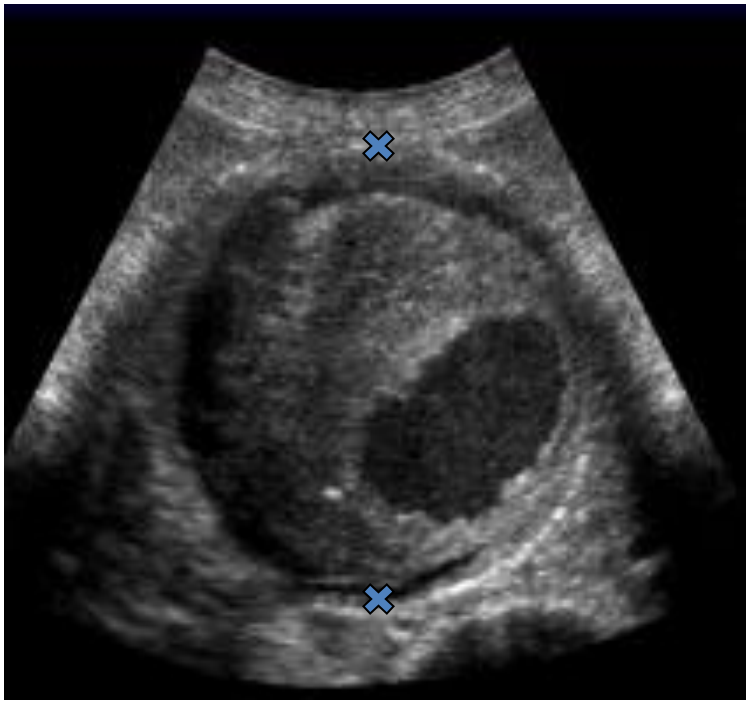

abominal aortic aneurysms

Correlation between 2 blinded ultrasound measurement

the proximal aorta

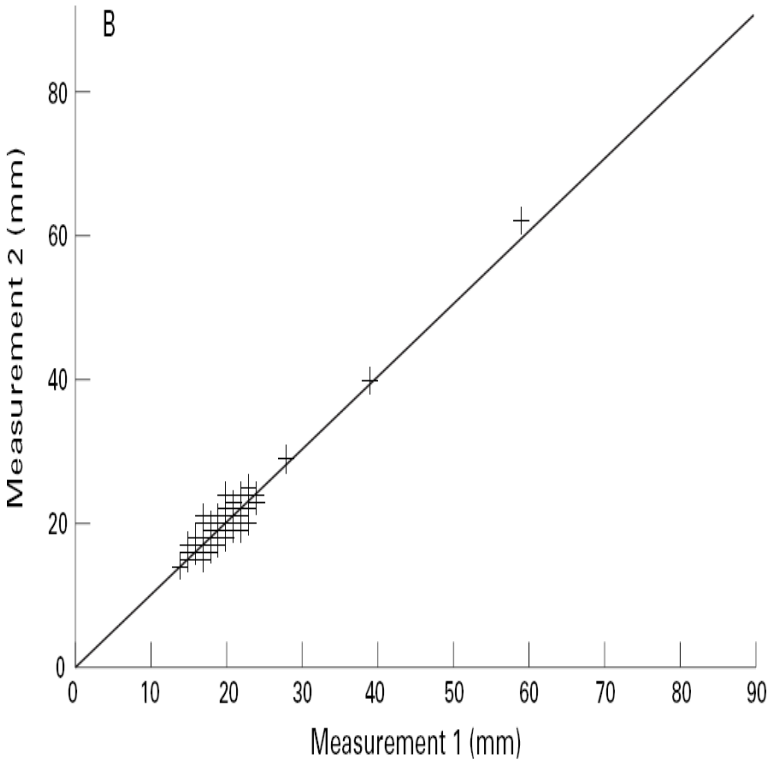

the distal aorta

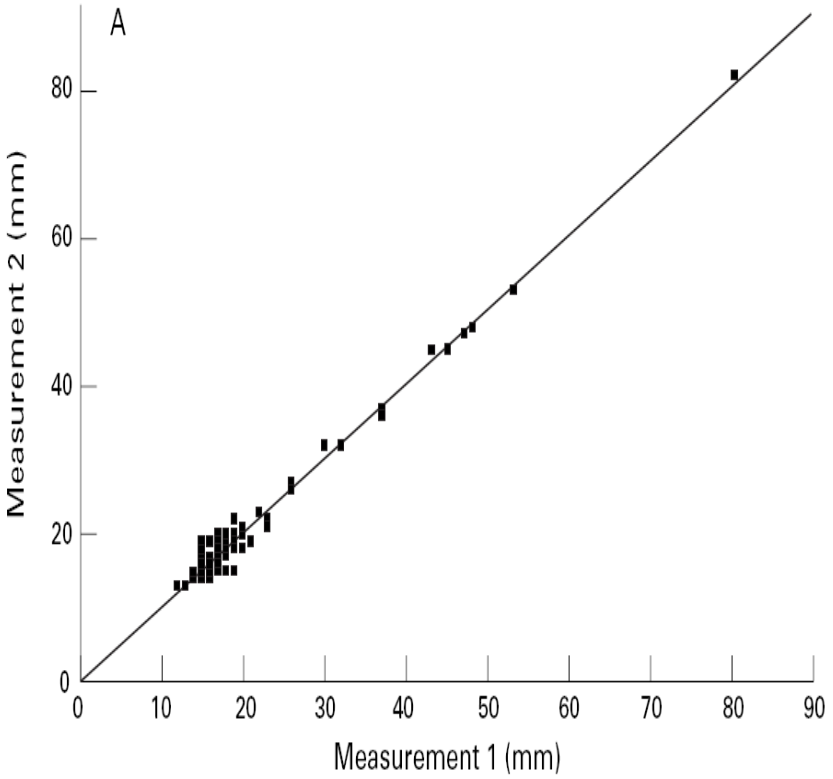

”….ultrasound readings of the proximal and distal aorta can be interpreted **within a range of +/- 3 mm**…..”

Pleumeekers et al J Med Screen 1998

abominal aortic aneurysms

- Infra- or suprarenal?
- Left renal vein is “easy”
- Renal arteries difficult

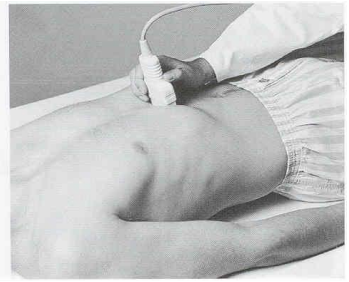

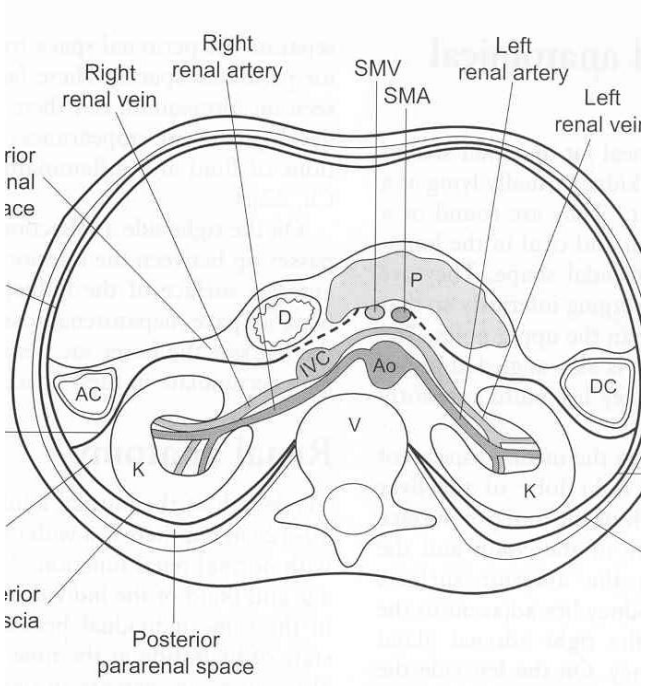

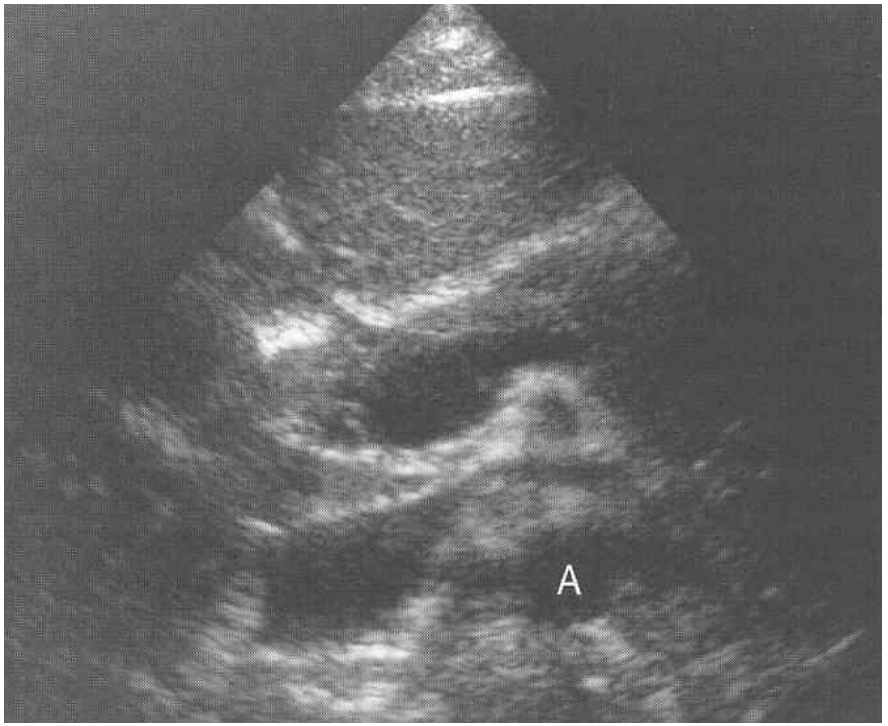

Limitations / pitfalls

- Poor visualization due to bowel gas or obesity
- Bowel movements
- Image depth to deep

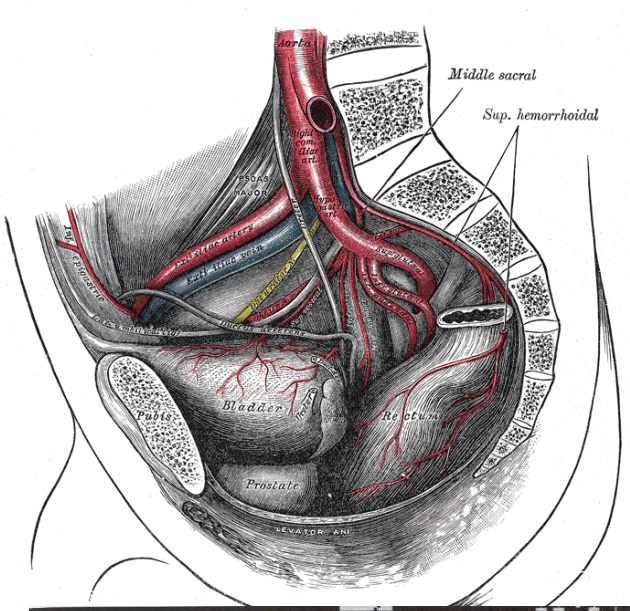

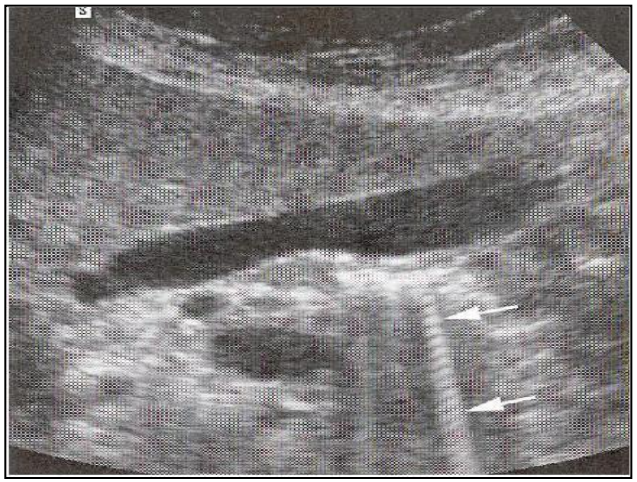

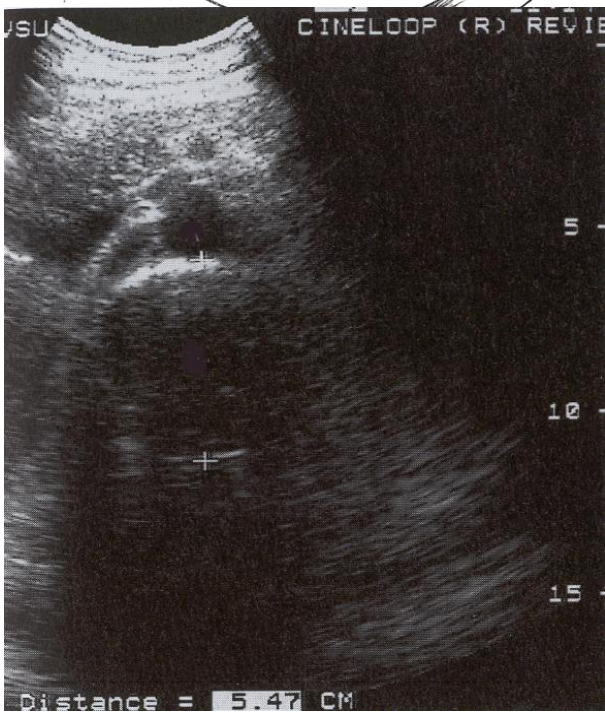

Ultrasound of the aorto-iliac for occlusive disease…..

- Duplex of the iliac arteries are **troublesome!**
- Poor visualization due to
  - bowel gas
  - obesity
  - deep and torturous course of the vessels
  - bowel movements
- **Time-consuming!**

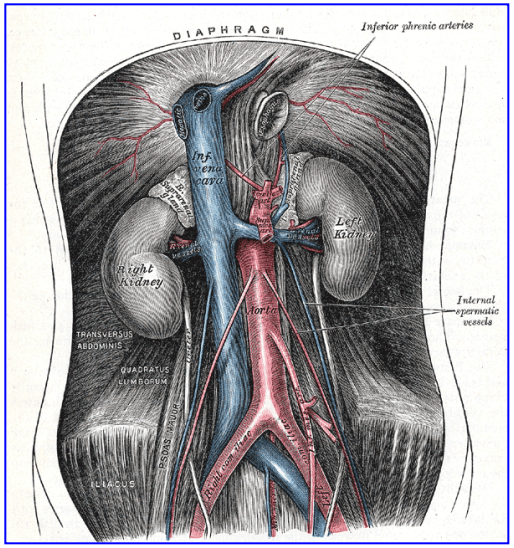

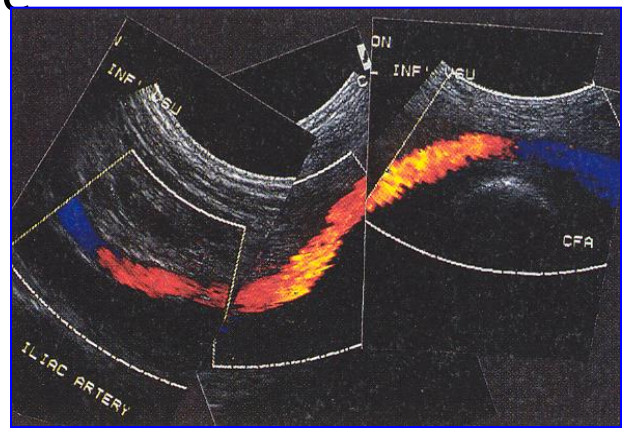

Visual interpretation of the Doppler waveform in CFA

- A normal waveform can safely exclude significant upstream aorto-iliac disease
  - A risk of <1% for false negative
  - Examination time: 2 min
  - Rationalize the use of arteriography

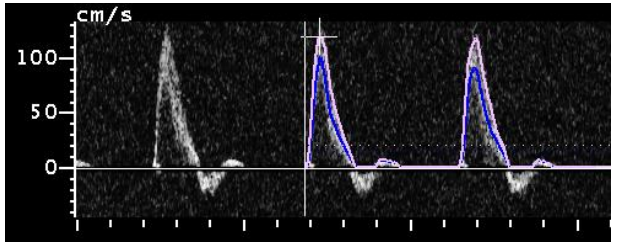

- An abnormal waveform
  - You must suspect an upstream disease
  - Aorto-iliac investigation necessary: Duplex or Arteriography (prepared for PTA)
  - Approximately 10% false positive

Eiberg, EJVES, 2001

US of the common femoral artery (CFA)

- Superficial
- Easy
- Quick (2 min)
- Minimal undressing of the patient

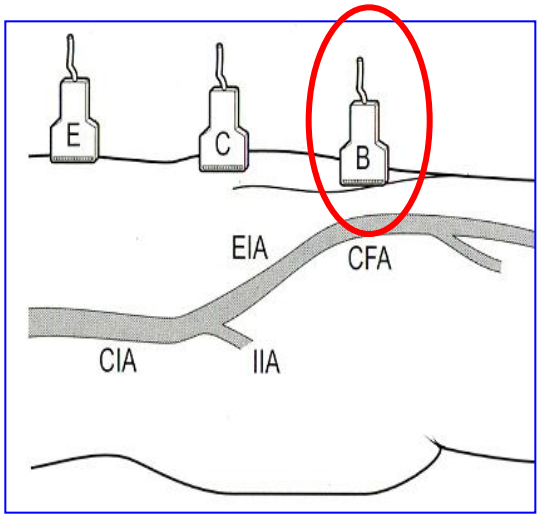

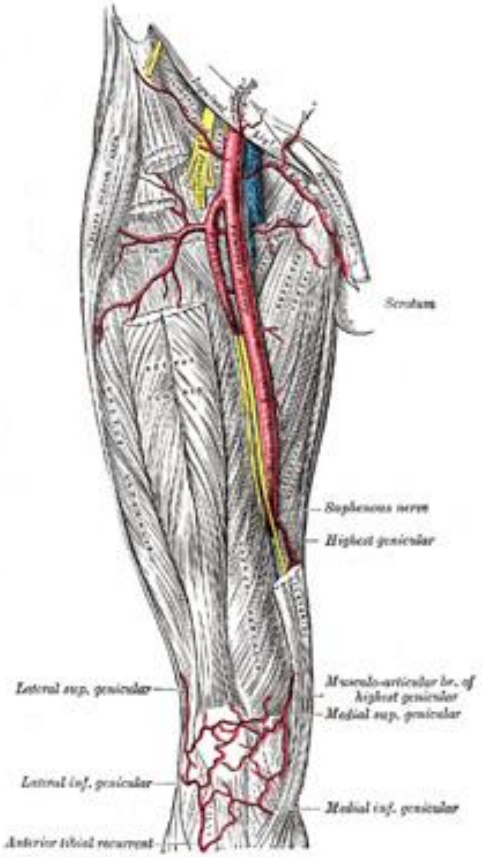

Doppler waveform in CFA

Abnormal

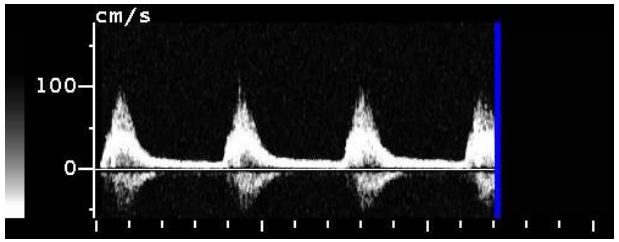

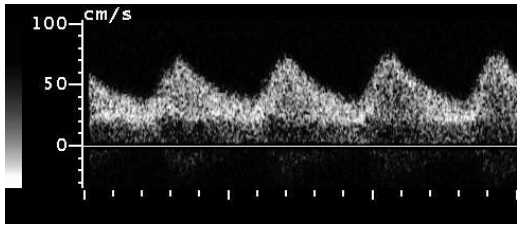

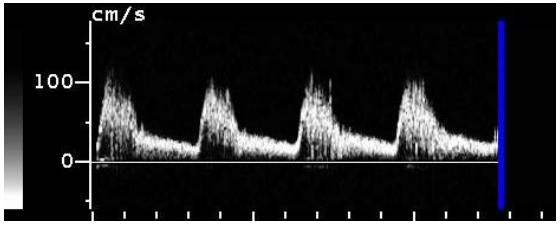

Normal

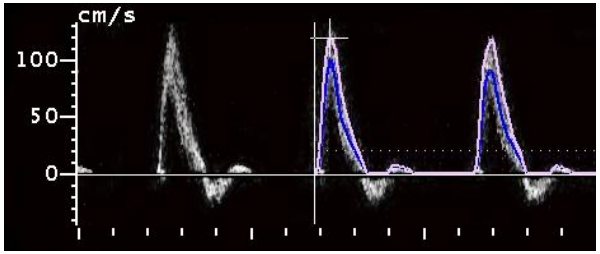

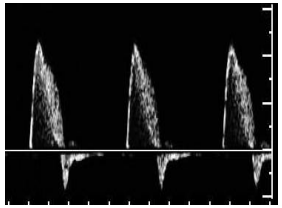

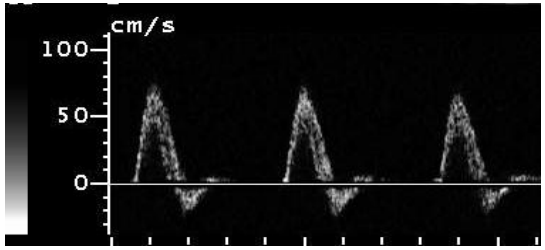

1. **A triphasic or biphasic waveform, including a reversed flow phase**
2. **A clear (visible) systolic spectral window**
3. **A low or absent positive end-diastolic flow**

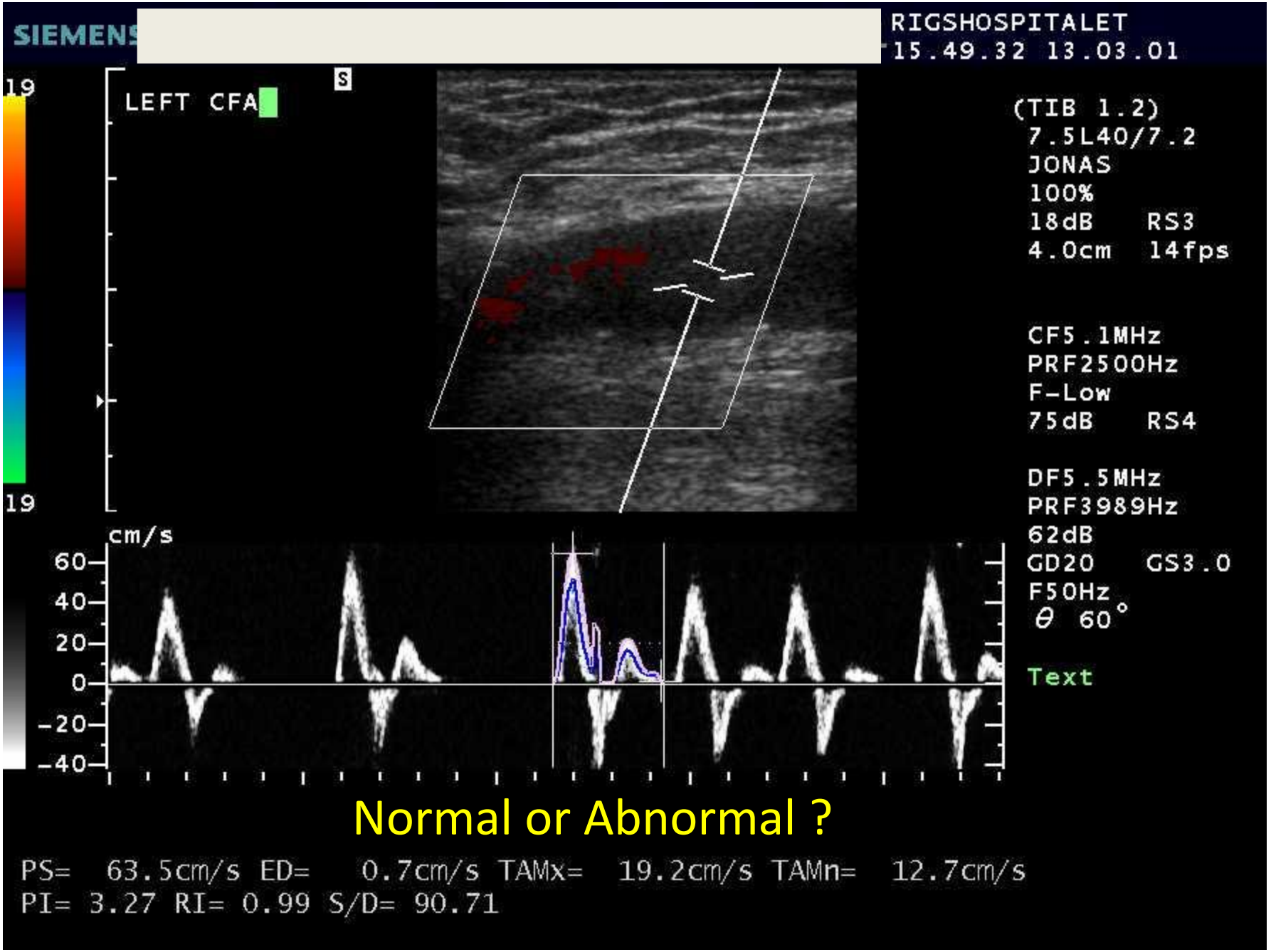
SIEMENS
RIGSHOSPITALET
15.49.32 13.03.01
19
LEFT CFA
S
(TIB 1.2)
7.5L40/7.2
JONAS
100%
18dB RS3
4.0cm 14fps
CF5.1MHz
PRF2500Hz
F-Low
75dB RS4
DF5.5MHz
PRF3989Hz
62dB
GD20 GS3.0
F50Hz
θ 60°
Text
19
cm/s
60
40
20
0
-20
-40
Normal or Abnormal ?
PS= 63.5cm/s ED= 0.7cm/s TAMx= 19.2cm/s TAMn= 12.7cm/s
PI= 3.27 RI= 0.99 S/D= 90.71

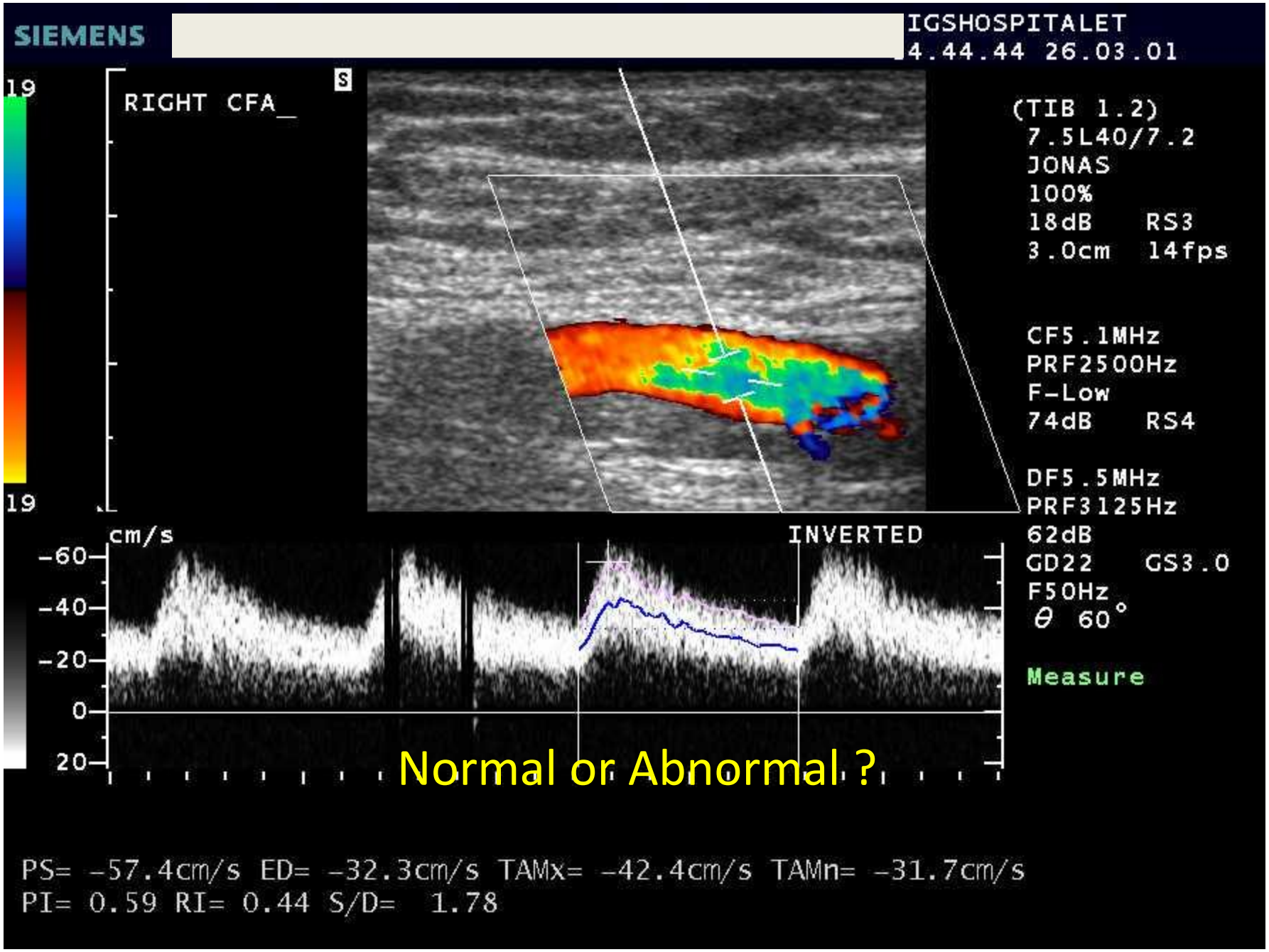
SIEMENS
IGSHOSPITALET
4.44.44 26.03.01
19
RIGHT CFA_
S
(TIB 1.2)
7.5L40/7.2
JONAS
100%
18dB RS3
3.0cm 14fps
CF5.1MHz
PRF2500Hz
F-Low
74dB RS4
DF5.5MHz
PRF3125Hz
62dB
GD22 GS3.0
F50Hz
θ 60°
Measure
19
cm/s
INVERTED
-60
-40
-20
0
20
Normal or Abnormal ?
PS= -57.4cm/s ED= -32.3cm/s TAMx= -42.4cm/s TAMn= -31.7cm/s
PI= 0.59 RI= 0.44 S/D= 1.78

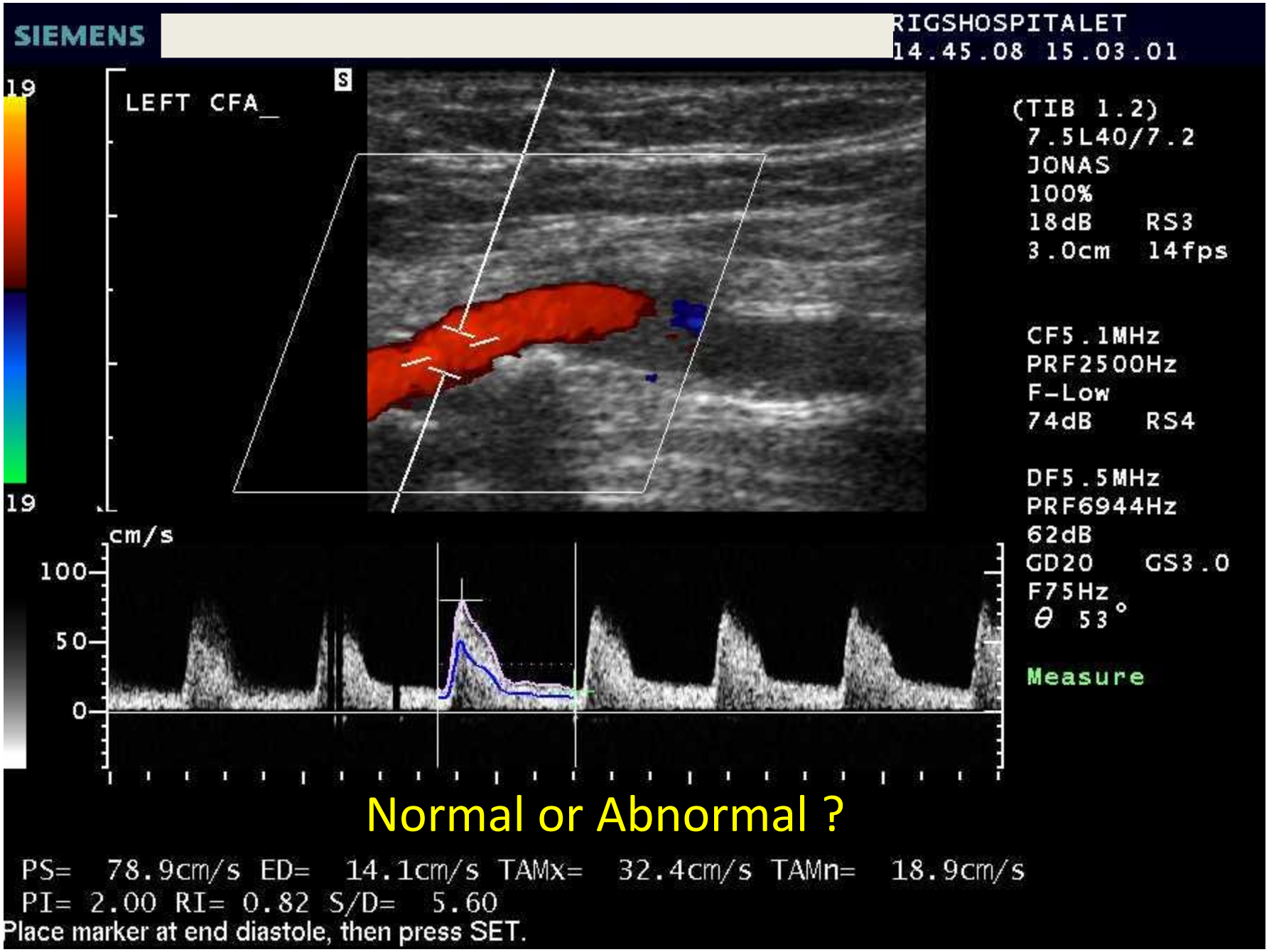
SIEMENS
RIGSHOSPITALET
14.45.08 15.03.01
19
LEFT CFA_
S
19
(TIB 1.2)
7.5L40/7.2
JONAS
100%
18dB RS3
3.0cm 14fps
CF5.1MHz
PRF2500Hz
F-Low
74dB RS4
DF5.5MHz
PRF6944Hz
62dB
GD20 GS3.0
F75Hz
θ 53°
Measure
cm/s
100
50
0
Normal or Abnormal ?
PS= 78.9cm/s ED= 14.1cm/s TAMx= 32.4cm/s TAMn= 18.9cm/s
PI= 2.00 RI= 0.82 S/D= 5.60
Place marker at end diastole, then press SET.

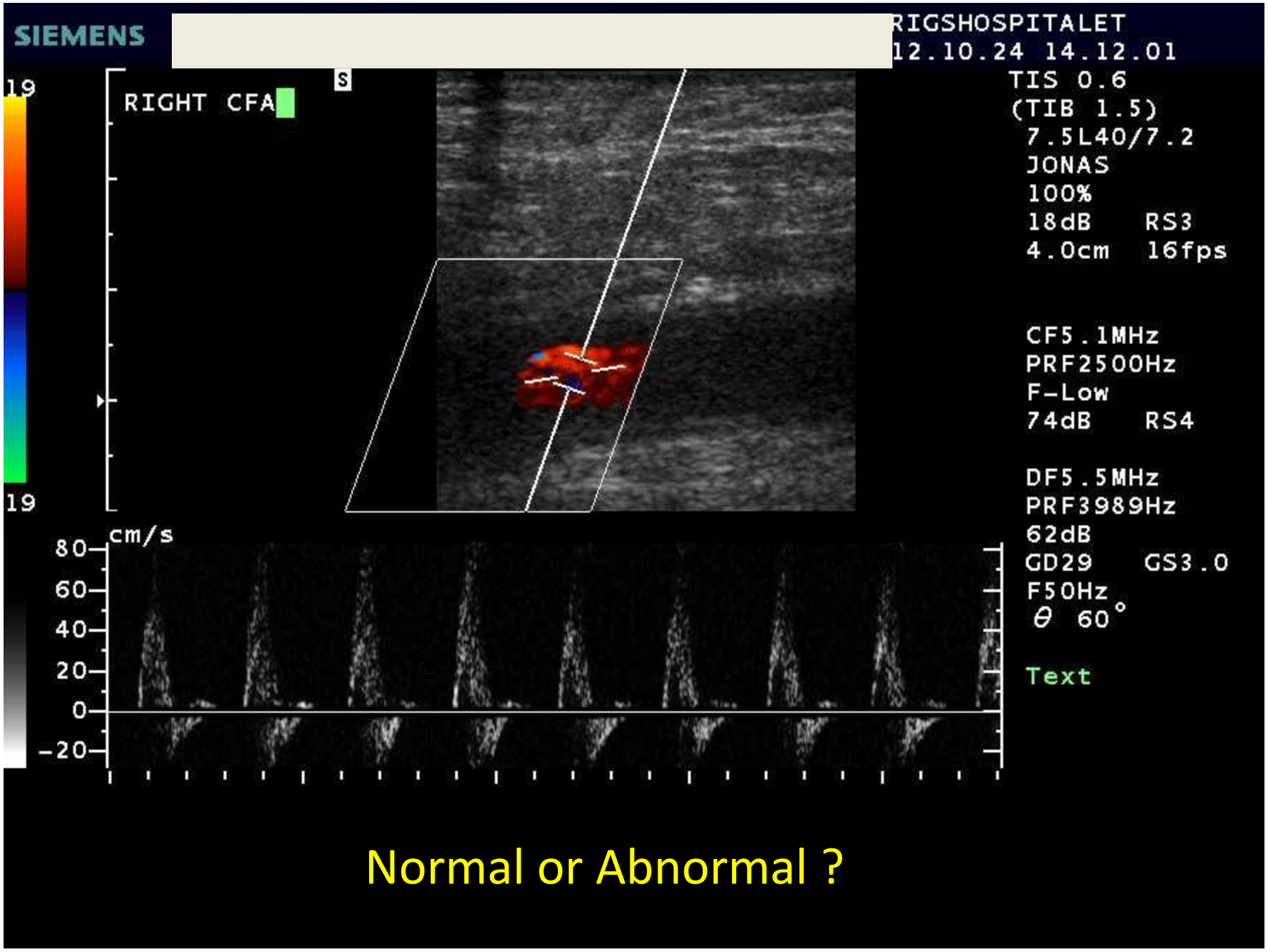
SIEMENS
RIGSHOSPITALET
12.10.24 14.12.01
RIGHT CFA
S
TIS 0.6
(TIB 1.5)
7.5L40/7.2
JONAS
100%
18dB RS3
4.0cm 16fps
CF5.1MHz
PRF2500Hz
F-Low
74dB RS4
DF5.5MHz
PRF3989Hz
62dB
GD29 GS3.0
F50Hz
θ 60°
Text
19
19
cm/s
80
60
40
20
0
-20
Normal or Abnormal ?

Flow profiles in stenoses

- Velocity increase
  - fluid travels faster through the narrow section

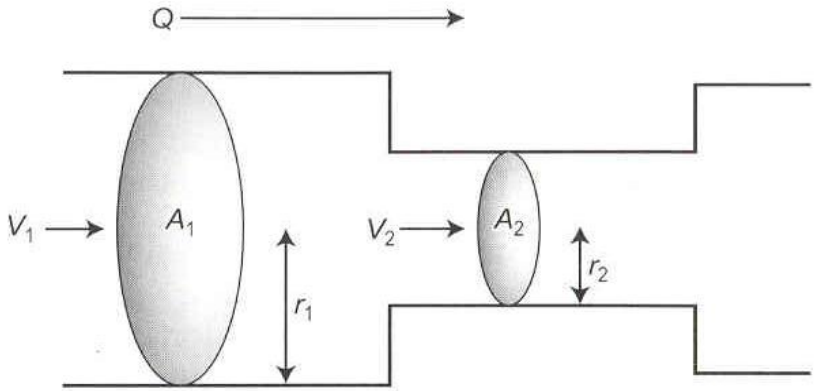

- Turbulence

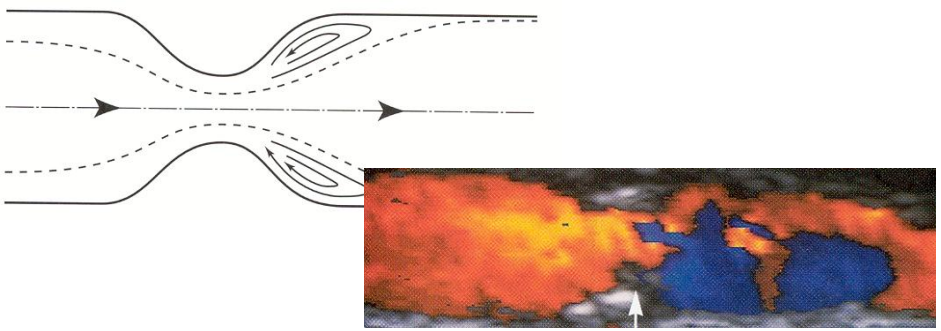

Peak systolic velocity ratio (PSVr)

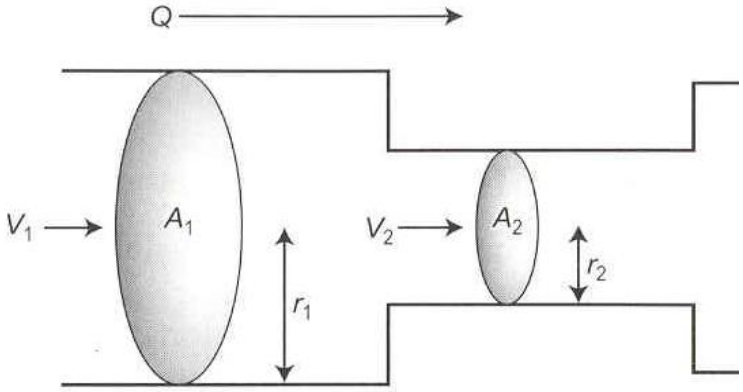

$$PSVr = \frac{\mathbf{V_2}\ \text{(Peak velocity in the stenosis)}}{\mathbf{V_1}\ \text{(peak velocity before the stenosis)}}$$

Velocity changes in stenoses

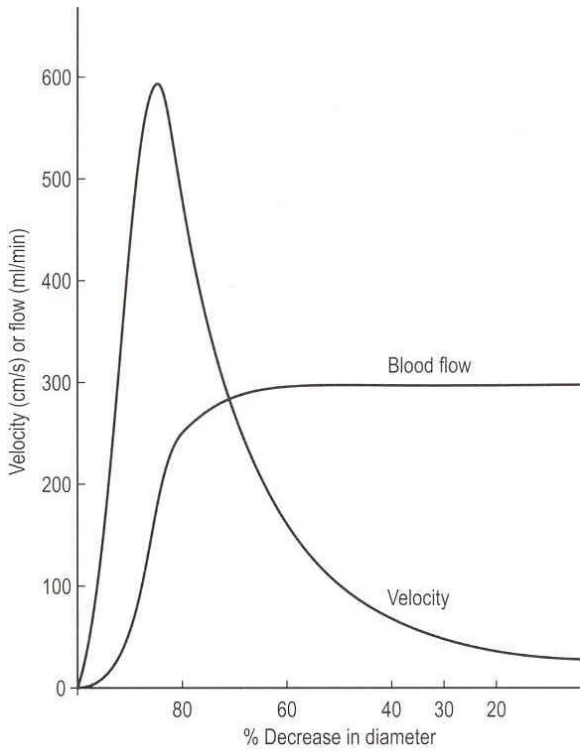

- At 70% reduction of diameter a pressure drop occur - and the stenosis are limiting the flow
- This correspond to a 2-3 fold increase in systolic velocity – or **PSVr > 2**

Velocity changes in stenoses

- >2 fold velocity increase
  = flow limiting stenosis

x3

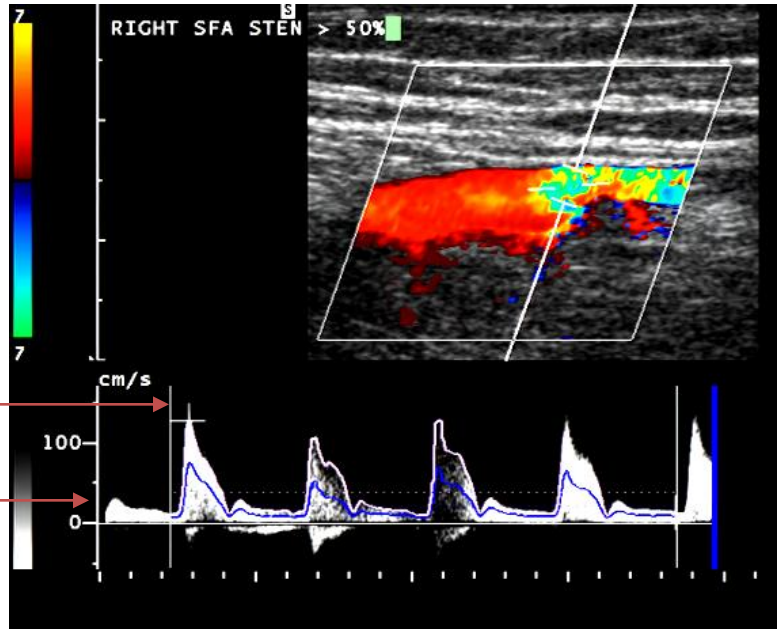

Occlusion

- No net forward flow on the Doppler waveform = *”occlusion signal”*

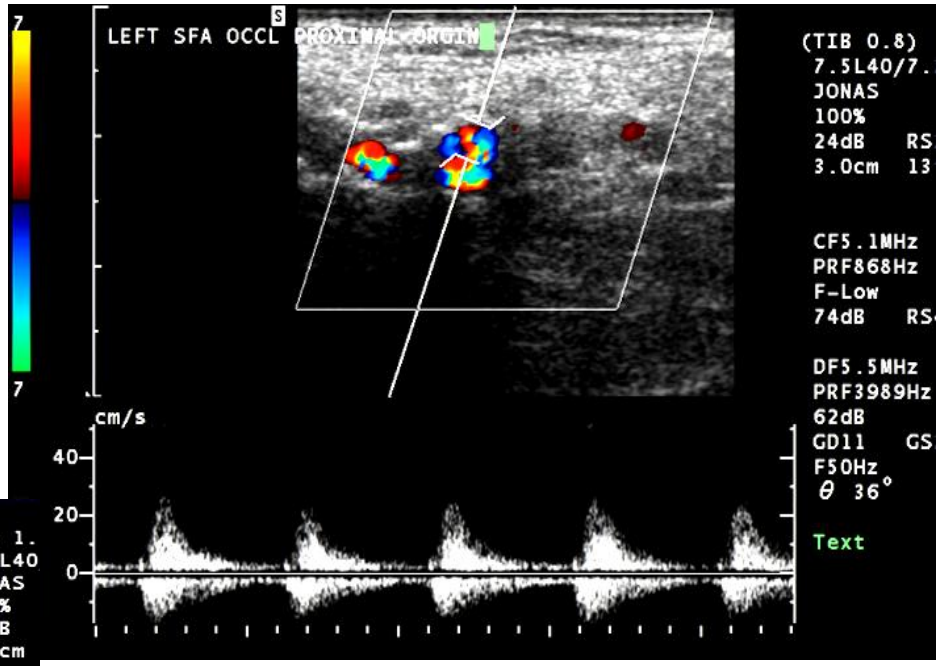

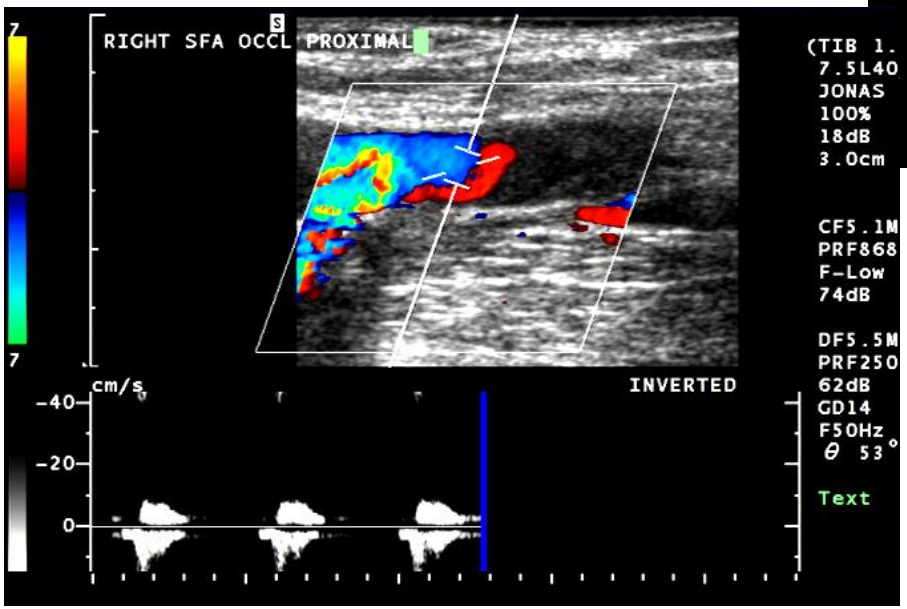

Duplex ultrasound of the femoro-popliteal segment

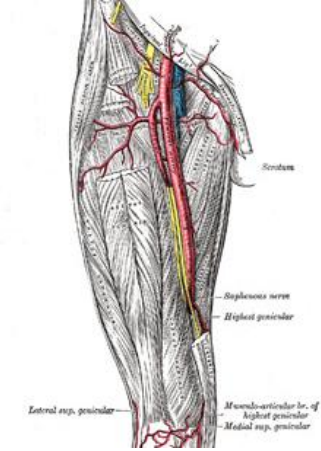

- In the femoro-popliteal segments duplex ultrasound has:
  - **Good agreement with arteriography** (Kappa≈0.80)
    (Sensier EJVES 96, Aly Br J Surg 98, London Br J Surg 99)
  - **Insignificant interobserver variation**
    (Eiberg EJVES 02)
- First choice in claudicants

femoro-popliteal segment

Duplex of the Superficial Femoral Artery

- Patient supine
- SFA <u>always</u> above the femoral vein
- Scan distal to the adductor canal
- Using 7.5 MHz transducer
- Velocity increase??

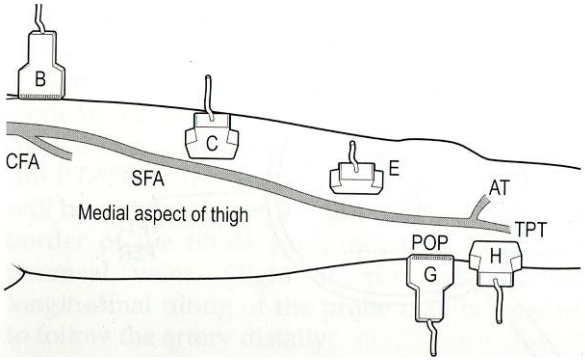

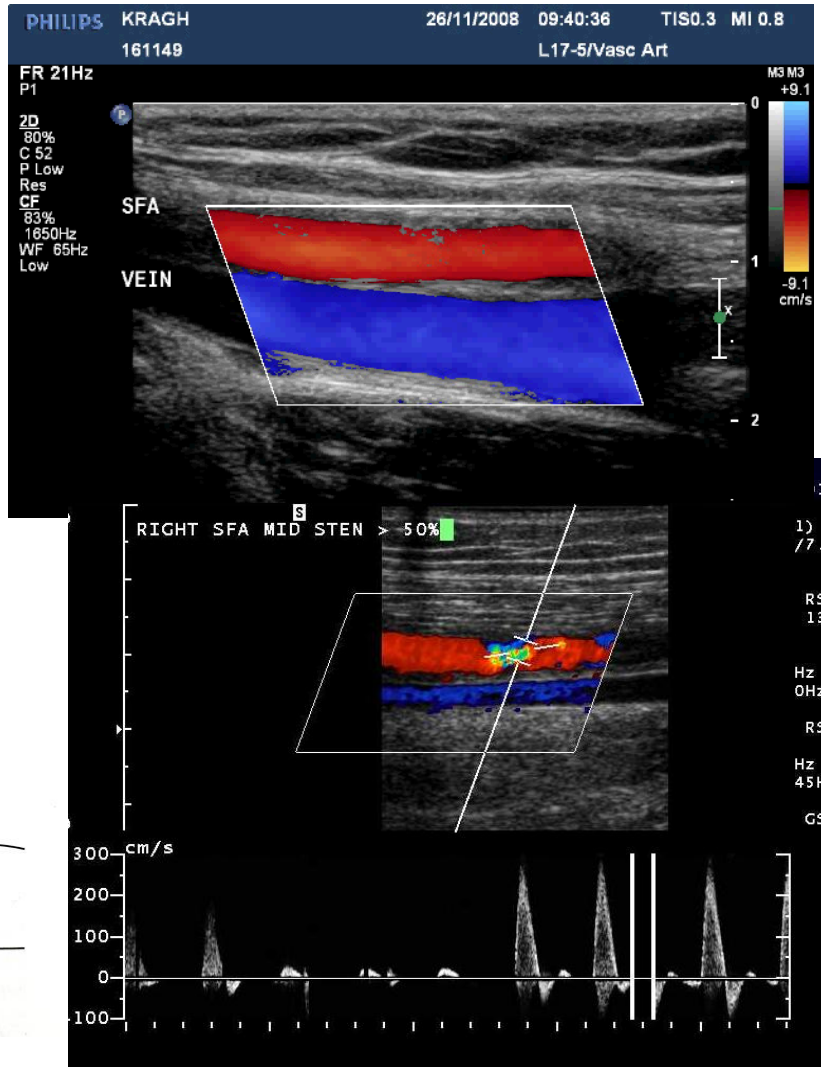

Duplex scanning of the Poplitea Artery

- Patient in lateral decubitus
- The relevant leg uppermost
- The popliteal artery under (=posterior) the vein
- Draw on the patient with a marker

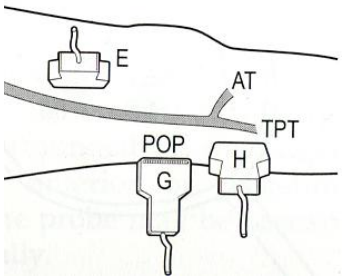

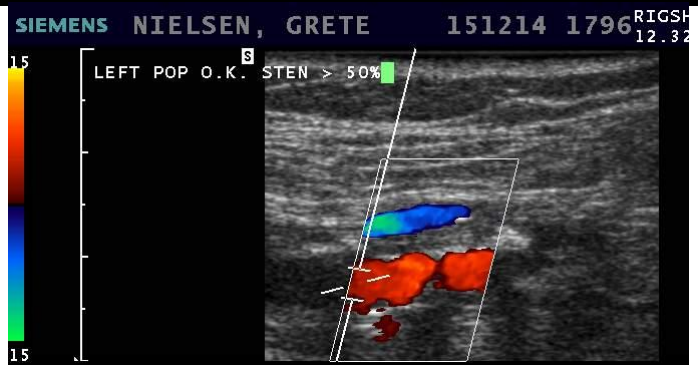

femoro-popliteal segment

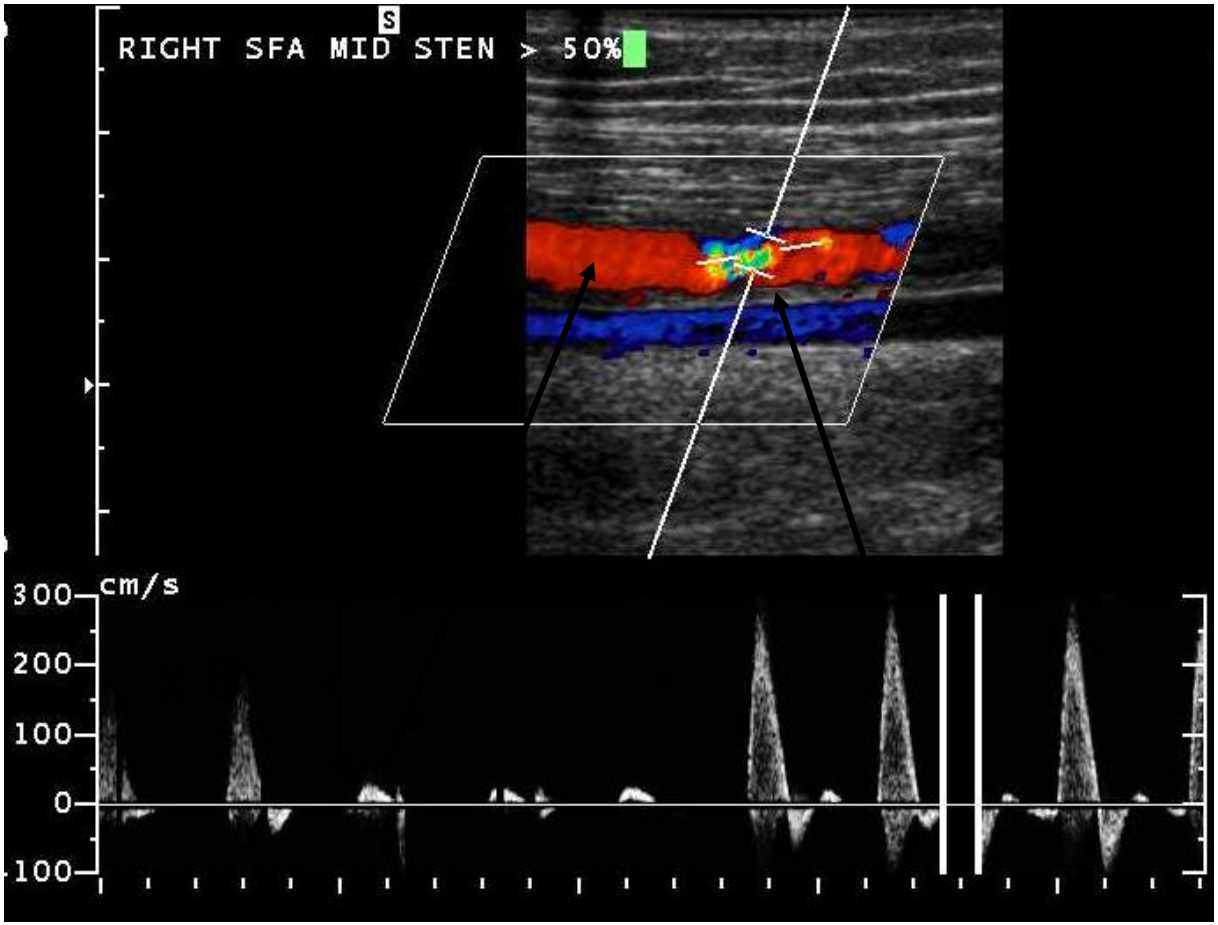

femoro-popliteal segment

Occlusion of the superficial femoral artery

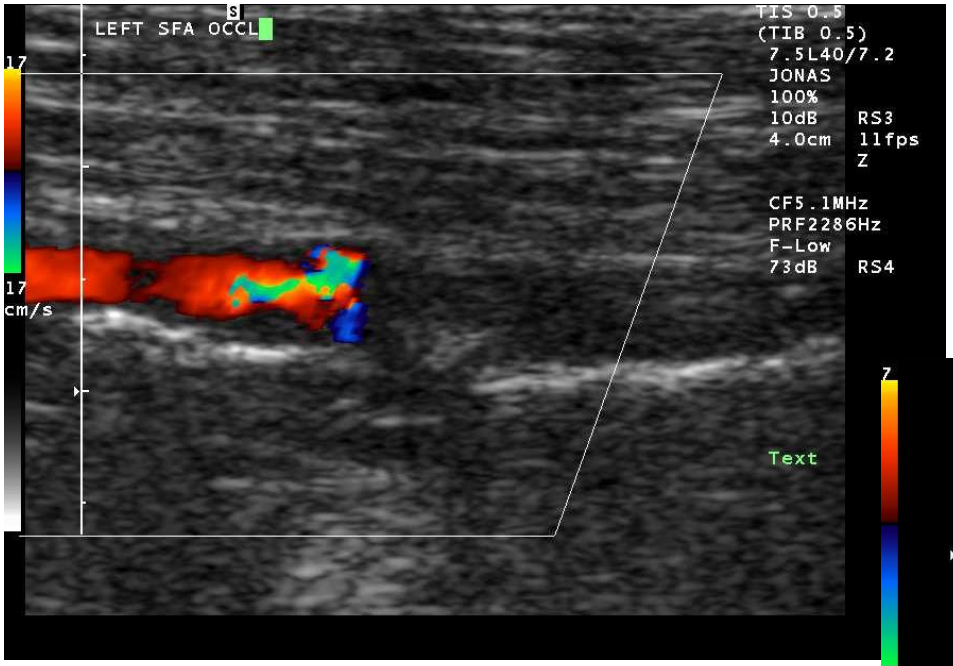

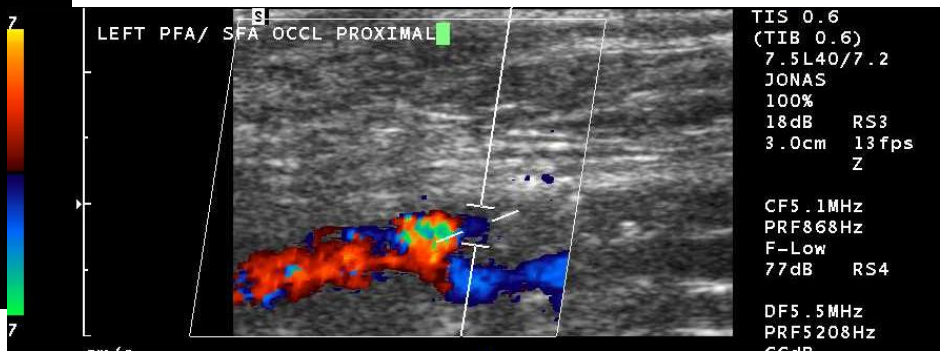

Purpose of duplex ultrasound of peripheral bypass

Vein grafts and duplex surveillance

- Many graft stenosis are asymptomatic and grafts may fail without warning (Indu, Legemate, Vasc Endovasc Surg 2005)
- Detecting increasing stenosis and planning angioplasty
- Graft surveillance: increase patency 15-20% (Lundell, JVS, 1995)

Program for graft surveillance

Normal duplex: 1M, 3M, 6M, 12M

Abnormal duplex:

- PSVr 2-2.9: close surveillance (every 1-2M)
- PSVr >3: consider angioplasty
- PSV < 45 cm/sec: consider graft defect
- Mono-phased waveform > 3M: consider graft defect

Blood flow in peripheral arteries and vein-grafts

Colour Doppler appearance

of triphasic flow

in normal peripheral arteries

and “established” vein graft

- forward and reversed flow are seen simultaneously during the diastolic phase

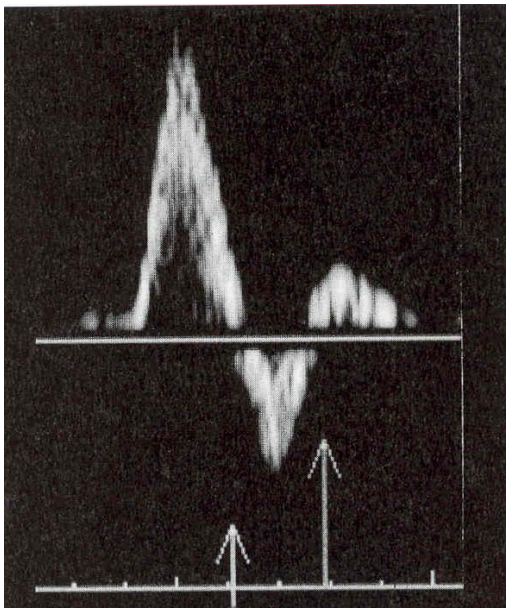



Blood flow in <u>new</u> vein-grafts

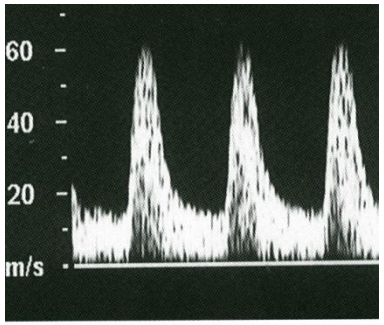

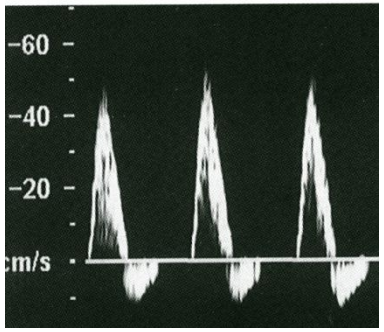

- Hyperemic monophasic flow profile due to sustained peripheral vasodilatation
- Later (≈3M): pulsatile, bi- or triphasic
- Except if arteriovenous fistulas: continued hyperemic high volume flow

Ultrasound of Varicose Veins

US of Varicose veins – the key questions

- Are there any superficial segments with reflux ?
  - Sapheno-femoral junction
  - Greater Sapehenous Vein on thigh
  - Sapheno-popliteal junction
  - Lesser Saphenous Vein on calf
- Are there normal deep veins, open without reflux ?
- Are the anatomy fairly normal ?
  - Double greater saphenous vein?

Reflux is the keyword: incompetent valves

- Retrograde flow > ½ sec. in standing position after released calf compression
  - Manually
  - Pneumatic
- Seen as a Doppler spectral curve
- Seen as a colour shift >½ sec.

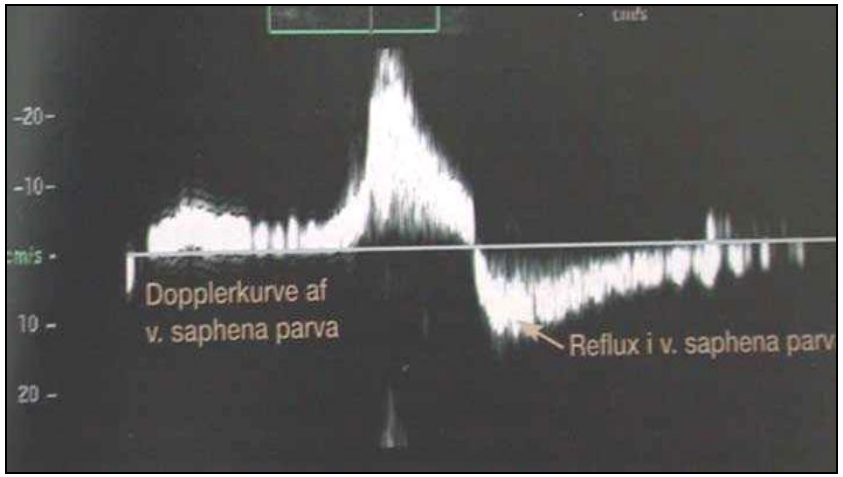

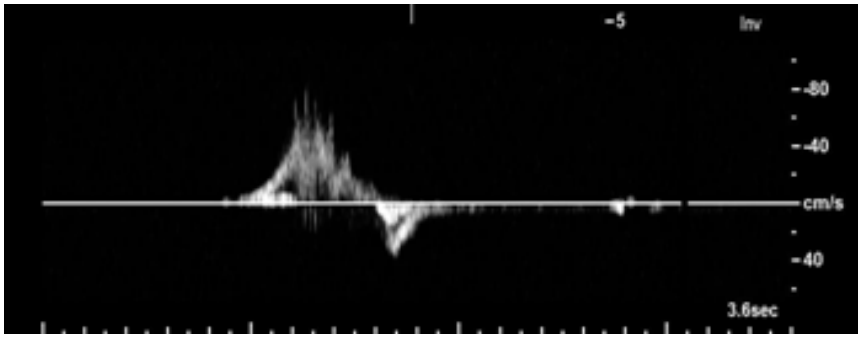

Standard examination with US

the groin

the inner side of the thigh

the popliteal fossa

"ADVANCED" vascular ultrasound

- Carotid, vertebral and subclavian arteries
- Renal and mesenteric arteries
- Iliac arteries
- Infra-genicular arteries
- Ultrasound contrast
- Ultrasound intervention (Pseudoaneurysms thrombin injection)

- *Only for a few dedicated technologist (MD's)*
- *Only in departments with interest and a dedicated ultrasound section*

24 06 31 - 0712 RK9 3111RK9
JENSEN,GRETHE EMILIE VANDAHL

NAVN: DATO:

Side	1. hø	2. ve	3. begge	9. na

Indikation	1a. >300m	1b. < 300m	2. hv.sm.	3. sår/gang	9. na

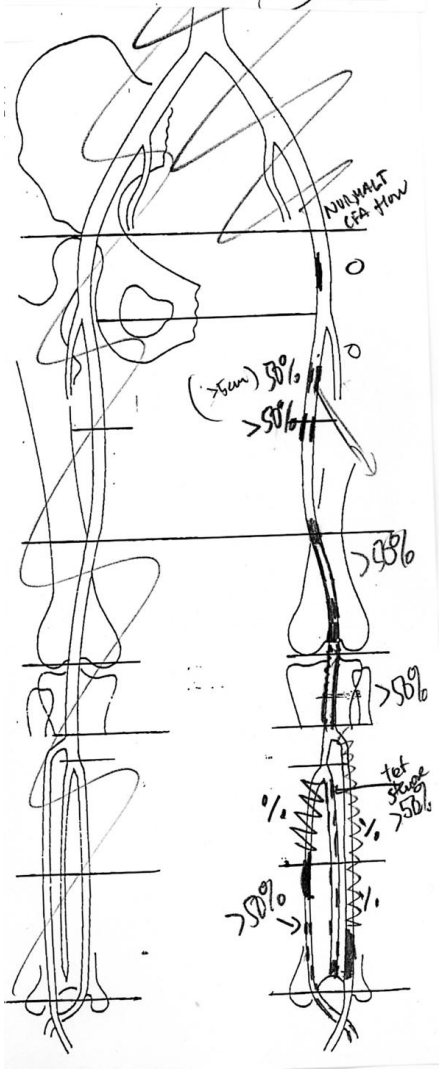

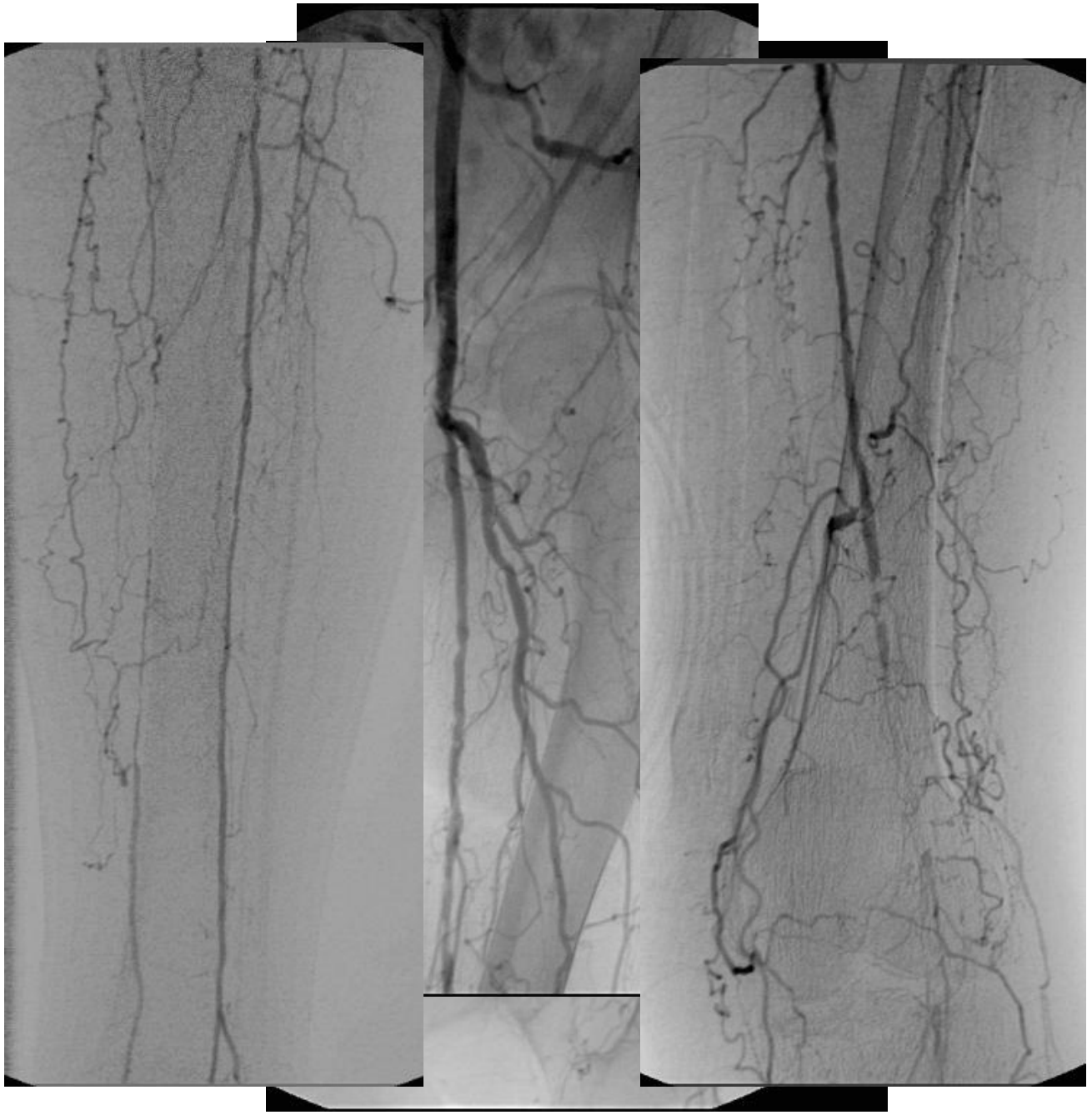

US of Infragenicular arteries

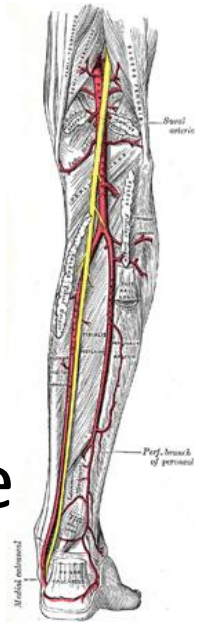

- Good agreement with DSA (Kappa≈0.70)
- The trifurcation and the peroneal artery the most difficult
- Experienced staff needed (>100 ex)
- Bypass surgery is performed without DSA in a few dedicated centers

Ultrasound contrast – vascular applications

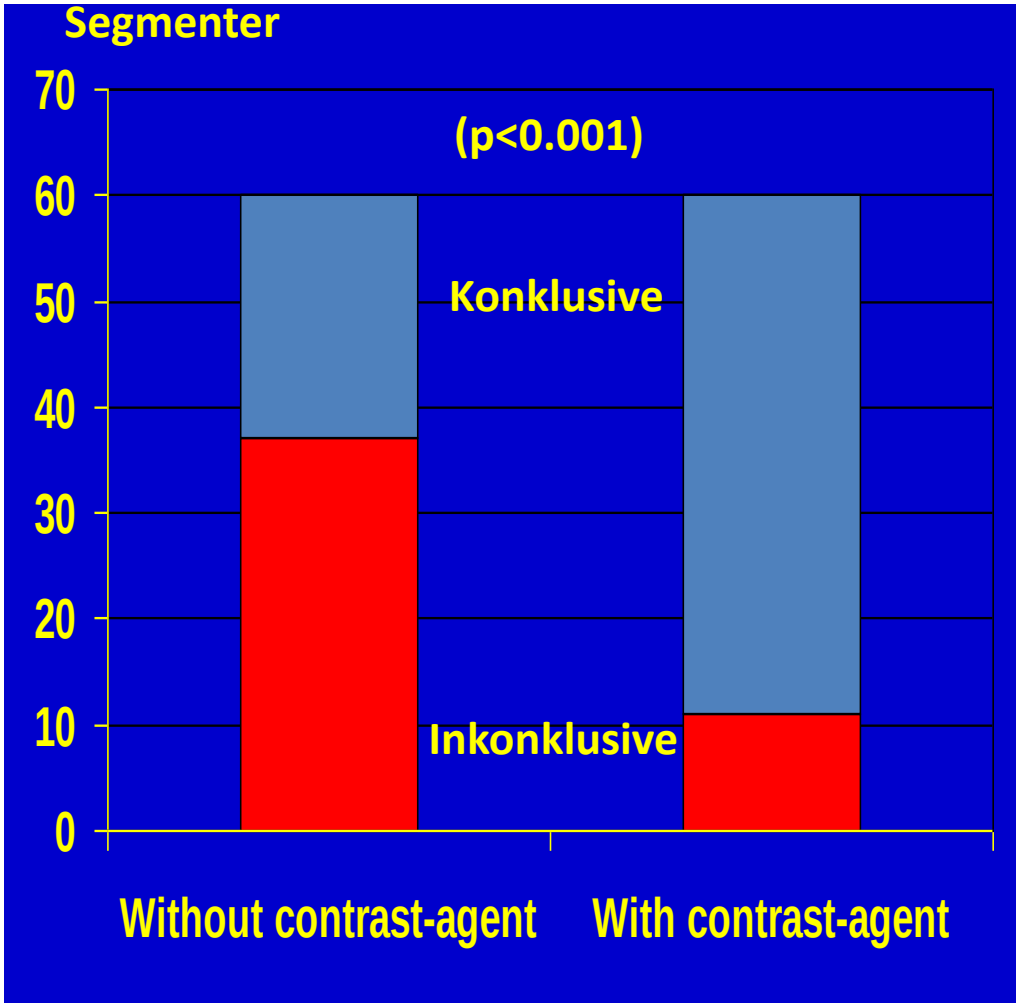

Eiberg et al., EJVES, 2002

Pseudo-aneurysms

- Following arterial puncture (0.5%)
- Ultrasound-guided compression > 75% success
- Ultrasound-guided thrombin injection

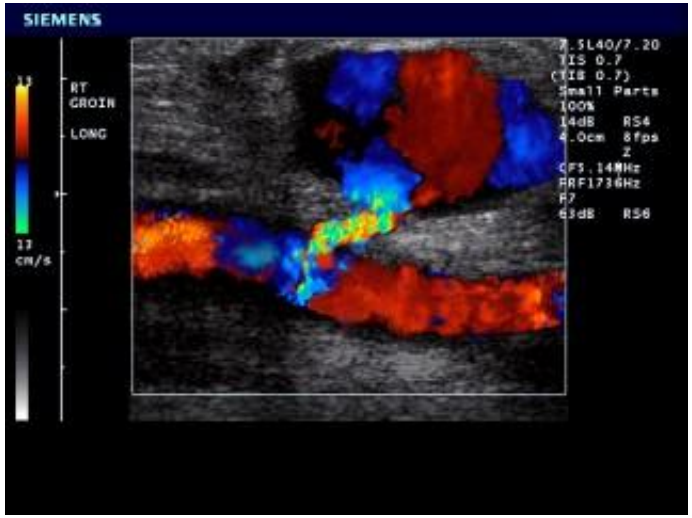

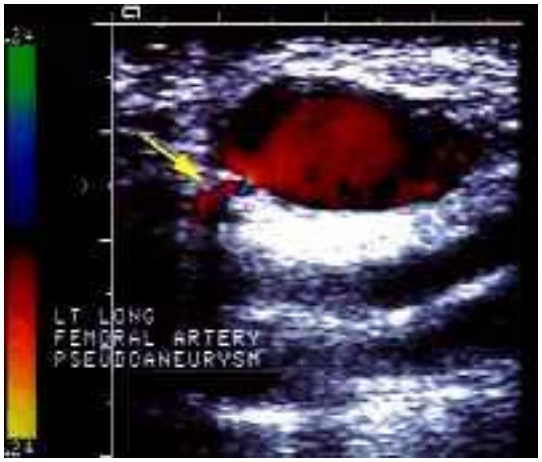

UL carotis
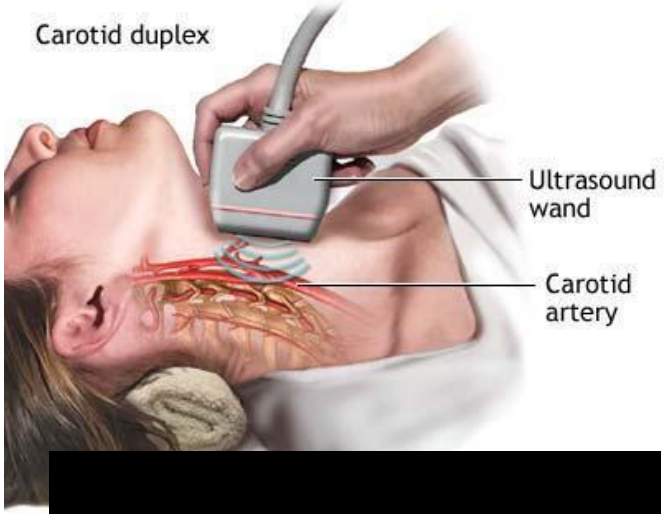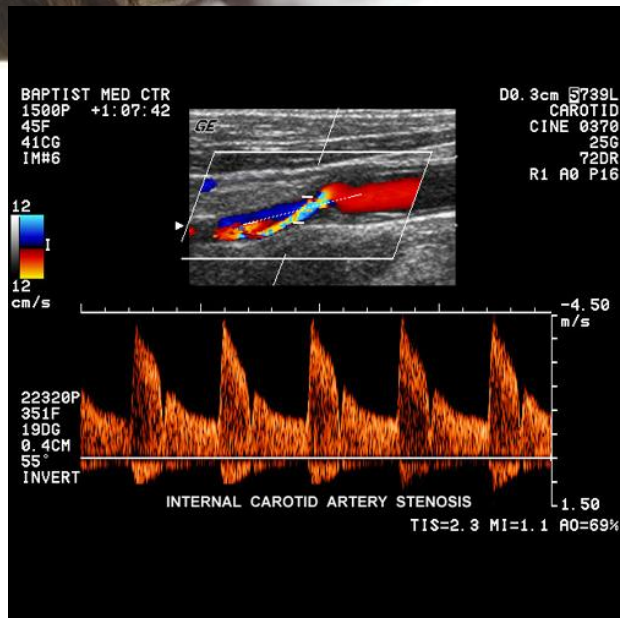
- Eneste præoperative diagnostiske metode før carotisendarterektomi
- Stenosegraden baseret på hæmodynamiske parametre, f.eks:
  - systolisk hastighed > 120 cm/s: >50% stenose
  - diastolisk hastighed > 135 cm/s: > 80% stenose
  - mm
- CT angio ved tvivl…